

Available online at www.sciencedirect.com

SciVerse ScienceDirect

journal homepage: www.elsevier.com/locate/etap

Ameliorative effect of silibinin against N-nitrosodimethylamine-induced hepatic fibrosis in rats

Devaraj Ezhilarasan, Sivanesan Karthikeyan*, Palani Vivekanandan

Food and Hepatotoxicology Laboratory, Department of Pharmacology and Environmental Toxicology, Dr. ALM. Post Graduate Institute of Basic Medical Sciences, University of Madras, Sekkizhar Campus, Taramani, Chennai 600 113, India

ARTICLE INFO

Article history:

Received 30 December 2011

Received in revised form 3 July 2012

Accepted 10 July 2012

Available online 31 July 2012

Keywords:

N-Nitrosodimethylamine

Silibinin

Hepatic fibrosis

Oxidative stress

Hepatic stellate cells

ABSTRACT

The protective effect of silibinin (SBN) against hepatic fibrosis induced by repeated intermittent administration of N-nitrosodimethylamine (DMN) was investigated in rats. Oral administration of SBN recovered body and liver weight loss and reversed the elevation of serum AST, ALT and ALP accompanied by their fall in the liver tissue in DMN-induced fibrotic rats. Severe oxidative stress induced in fibrotic rats was evidenced by two to three fold elevation in MDA and protein carbonyl levels associated with a fall in the activities of SOD and CAT in repeated DMN treatment and this adversity was protected by SBN post-treatment. Further, the fall in the activities of ATPases and increase in the levels of hydroxyproline and collagen observed in the liver tissue of DMN treated rats was prevented and reversed back toward normalcy by SBN post-treatment. Recovery of rat liver tissue against DMN-induced hepatocellular necrosis, inflammatory changes and hepatic fibrosis by SBN treatment is also confirmed by both H & E and Masson's trichrome stained histopathological evaluation of liver tissue. In conclusion, SBN exhibit hepatoprotective, antioxidant, free radical scavenging, membrane stabilizing and anti-fibrotic activity against DMN-induced hepatic fibrosis suggesting that it may be useful as a therapeutic agent toward amelioration of hepatic fibrosis.

© 2012 Elsevier B.V. All rights reserved.

1. Introduction

Hepatic fibrosis represents the wound healing response of the liver to diverse and repeated injuries. It is characterized by increased deposition and altered composition of extra-cellular matrix protein in the liver (Du et al., 1999). Several experimental and clinical evidences have shown common link between chronic liver injury, oxidative stress, activation of hepatic stellate cells (HSCs) and their transformation to myofibroblast-like cells, associated with increased production of extra-cellular matrix proteins during hepatic fibrosis (Poli, 2000; Friedman, 1993). Repeated administration of N-nitrosodimethylamine (DMN), a potent hepatotoxin,

carcinogen and mutagen has been demonstrated to induce bridging fibrosis, necrosis and collapse of parenchymal framework of liver (George et al., 2001; Ala-Kokko et al., 1987). Accumulation of extra-cellular matrix protein, especially collagen, associated with increase in oxidative stress and lipid peroxidation has been reported in DMN-treated rats (Vendemiale et al., 2001). Hence, DMN-induced hepatic fibrosis is suggested as a good and reproducible model for studying pathophysiological and biochemical changes associated with hepatic fibrosis and cirrhosis for screening of anti-fibrotic agents (George et al., 2001; Jézéquel et al., 1989).

Silibinin (SBN), a natural polyphenolic flavonoid is a major ingredient, constituting around 60–70% of silimarin (SIL), which is isolated from medicinal plant *Silybum marianum* and

* Corresponding author. Tel.: +91 44 2454 7144; fax: +91 44 2454 0709; mobile: +91 44 94441 08748.

E-mail addresses: sivanesankarthikeyan@hotmail.com, karthik48y@yahoo.co.in, hepatotoxicology.lab@gmail.com (S. Karthikeyan).
1382-6689/\$ – see front matter © 2012 Elsevier B.V. All rights reserved.
<http://dx.doi.org/10.1016/j.etap.2012.07.004>

it has been shown to protect the liver against alcohol, carbon tetrachloride, thalium, phenylhydrazine and many other drugs and chemicals induced liver injury in human and experimental animals (Gazak et al., 2007; Valenzuela et al., 1985). The present investigation was undertaken with the objective to evaluate the anti-fibrotic, antioxidant and protective efficacies of SBN against repeated DMN-induced hepatic fibrosis in rats due to lacunae of studies.

2. Materials and methods

2.1. Chemicals

N-Nitrosodimethylamine (density 1.01 g/ml), silibinin, 1,1,3,3-tetra methoxypropane, thiobarbituric acid, L- α -glutamyl-p-nitroaniline, malondialdehyde and 5-5' bis thio (2-nitrobenzoic acid) were purchased from M/s Sigma-Aldrich Chemicals, USA. All the other chemicals used for various assay procedures were purchased locally and were analytical grade.

2.2. Animals

Wister albino rats of either sex, weighing 180 ± 20 g, housed in controlled environmental conditions (temperature— $24 \pm 2^\circ\text{C}$; relative humidity—50–70%; 12 h light/dark cycle) were used in this study. The animals were provided standard pellet diet and water ad libitum. Institutional animal ethical committee permission was obtained before performing the experiments (IAEC No. 02/09/2011).

2.3. Experimental protocol

Twenty-four rats, were administered DMN on the first 3 consecutive days of each week for 3 weeks to induce hepatic fibrosis as described previously (George et al., 2001). Six animals died due to internal hemorrhage and severe ascetics during in the third week of DMN administration. The surviving 18 rats were randomly divided into three groups (as Groups II, III and IV), each comprising of six nos. The Group II rats were sacrificed 24 h after last DMN administration (i.e., on day 22). While Group III rats were left without any treatment after last DMN dosage, for a further period of two weeks (i.e., till day 36); that of Group IV were post-treated with SBN for the same period. Group I rats received saline till day 21 and from day 22 till day 36, they receive propylene glycol orally. Group V received saline for three weeks period (i.e., till day 21) and then, they were treated SBN alone for further period of two weeks (i.e., from day 22 till day 36). Except Group II, all the other groups of rats were sacrificed on day 37. DMN was minced in saline and was administered at 10 mg/kg/day (i.p.). SBN, placed in propylene glycol was administered orally at 100 mg/kg/day (for 15 days). The dosage of SBN was selected based on our previous studies (Harrison Immanuel et al., 2010). The volume of saline, DMN and SBN were maintained at 0.3 ml/100 g b.w. of the animals and were prepared just before use.

2.4. Sample collection and preparation

Blood was collected from overnight fasted, ether-anesthetized rats from retro-orbital-plexus and was allowed to clot at cold. The clear supernatant serum was separated by centrifugation (at 2500 rpm for 15 min) of the clotted blood and its aliquot was stored at cold (4°C) until further analysis.

The animals were sacrificed by decapitation and the livers were quickly excised, washed in saline to remove blood clot and other tissue debris and were blotted to dryness. The 1% and 10% homogenates of liver tissue were prepared using Tris-HCl buffer (0.1 M; pH-7.4). The homogenates were centrifuged to remove cell debris and the clear supernatants were used for various biochemical assay.

A piece of liver tissue (approximately 5 mm cube) was fixed in phosphate buffered formal saline (pH 7.4) for use in histopathological evaluation.

2.5. Assay of transaminases (AST, ALT) and alkaline phosphatase (ALP)

The activities of AST and ALT in serum and liver tissue homogenates were estimated as detailed by Reitman and Frankel (1957). This assay evaluates the quantity of pyruvate liberated by these enzymes and their hydrozone formation on its treatment with 2,4-dinitrophenyl hydrazine and sodium hydroxide.

The phenol liberated by the enzyme in the presence of the substrate disodium phenyl phosphate at alkaline pH was treated with Folin's phenol reagent and sodium carbonate to form a blue colored complex which was estimated spectrophotometrically for the assay of ALP in serum and liver tissue (King, 1965).

2.6. Lipid peroxidation (LPO)

Malondialdehyde, formed as the end product by the peroxidation of lipids was reacted with thiobarbituric acid to form a colored complex, whose absorbance was measured spectrophotometrically for the assay of LPO in liver tissue homogenates (Ohkawa et al., 1979).

2.7. Total carbonyl content

The carbonyl content of liver tissue was estimated as described by Levine et al. (1990). Briefly, the carbonyl groups present in the liver tissue proteins were oxidized and allowed to react with 2,4-dinitrophenyl hydrazine to form a color, which was estimated using spectrophotometer.

2.8. Superoxide dismutase

Superoxide dismutase (SOD) was estimated as described by Marklund and Marklund (1974). The degree of inhibition of autooxidation of pyrogallol by the enzyme present in the liver homogenate at alkaline pH was measured using spectrophotometer.

Table 1 – Liver weight and body weight changes in rats treated with DMN and SBN.

Treatment groups	Parameters		
	Liver weight (g)	Body weight (g)	Liver weight Body weight ratio
Group I	6.20 ± 0.28	192.50 ± 9.91	3.22 ± 0.18
Group II	4.47 ± 0.77 ^{***,a}	173.17 ± 6.11 ^{*,a}	2.59 ± 0.47 ^{*,a}
Group III	4.41 ± 0.70 ^{***,a}	176.33 ± 13.23 ^{*,a}	2.51 ± 0.41 ^{*,a}
Group IV	5.58 ± 0.43 ^{*,b}	181.83 ± 5.49	3.07 ± 0.30
Group V	6.05 ± 0.48	189.67 ± 8.16	3.23 ± 0.27

Values are mean ± S.D. of 6 rats. Groups II and III rats were sacrificed on days 22 and 36, respectively.

^a Compared with Group I.

^b Compared with Group II.

* $p < 0.05$.

** $p < 0.01$.

*** $p < 0.001$.

2.9. Catalase

The dichromate in acetic acid was reduced to chromic acetate when heated in the presence of hydrogen peroxide, liberated by the enzyme present in liver tissue homogenate forms an unstable intermediate, i.e., chromic acetate, which was measured spectrophotometrically as described by [Sinha \(1972\)](#).

2.10. ATPases

The activities of Na⁺/K⁺ ATPase and Ca²⁺ ATPase ([Hjerten and Pan, 1983](#)) and Mg²⁺ ATPase ([Ohnishi et al., 1982](#)) were estimated in the liver tissue. In these assays, the phosphate liberated by these enzymes was quantified as described by [Fiske and Subbarow \(1925\)](#).

2.11. Hydroxyproline and collagen

The liver tissue (around 100 mg) was hydrolyzed in 6 N HCl in sealed tubes at 110 °C for 16 h and was subsequently evaporated to dryness to remove acid. The residue was dissolved in water, filtered and the filtrate was quantified using spectrophotometer. The collagen content of the liver tissue was calculated by multiplying the hydroxyproline values by the factor 7.46 as described by [Neuman and Logan \(1950a,b\)](#).

2.12. Protein assay

The serum and liver tissue samples were estimated by the standard method of [Lowry et al. \(1951\)](#).

2.13. Histopathology studies

The liver tissues, fixed in phosphate buffered formal saline were dehydrated and embedded in paraffin as blocks. They were then sectioned (8 µm thickness), spread on glass slides and were stained by hematoxyline and eosin (H & E). They were subsequently destained and mounted permanently. Some of these spread sections were stained with Masson's trichrome, to determine the extent of fibrosis as described by [Bancroft and Cook \(1984\)](#).

2.14. Statistical analysis

The values are presented as mean ± S.D. The data were subjected to one-way analysis of variance (ANOVA) and the post hoc multiple comparison tests to assess the degree of significance of difference between means of various treatment groups were performed by employing Tukey's test, using SPSS software (version 16.0). The "p" value < 0.05 was considered significant.

3. Results

3.1. Body and liver weight changes

DMN alone treated rats (Groups II and III) were docile, weak and show significant fall in body weight ($p < 0.01$), liver weight ($p < 0.001$) and their ratio ($p < 0.01$), when compared to saline treated control (Group I). This adversity was significantly protected and reversed back to normalcy in rats post-treated by SBN after DMN treatments (Group IV). The viscera showed various degrees of ascetics in rats receiving DMN alone. However, SBN alone treated rats (Group V) did not show any change in body weight and liver weight when compared to control ([Table 1](#)).

3.2. AST, ALT, ALP and protein

DMN alone treatments (Groups II and III) caused more than two-fold increase ($p < 0.001$) in the activities of AST, ALT and ALP and a fall ($p < 0.01$) in the status of protein in serum. In the liver tissue, these treatments caused a highly significant fall ($p < 0.01$) in all the above parameters when compared to saline treated control (Group I), indicating hepatotoxic potential of this treatment. All the above adversities induced by DMN were significantly protected and reversed back toward normalcy in both serum and liver tissues of rats post-treated with SBN (Group IV), indicating hepatoprotective properties of this treatment against DMN-induced liver damage. SBN alone treatment (Group V) did not produce any change in the above parameters in both serum and liver tissue and they were comparable to saline treated control ([Table 2](#)).

Table 2 – Changes in transaminases, ALP and protein in serum and liver tissue of rats treated with DMN and SBN.

Treatment groups	Parameters			
	AST	ALT	ALP	Protein
Serum				
Group I	41.42 ± 3.43	43.01 ± 3.19	105.01 ± 4.58	7.01 ± 0.42
Group II	112.09 ± 0.59 ^{***,a}	102.55 ± 7.87 ^{***,a}	332.91 ± 13.34 ^{***,a}	5.68 ± 0.33 ^{**,a}
Group III	94.78 ± 10.69 ^{***,a}	97.13 ± 6.15 ^{***,a}	195.82 ± 33.57 ^{***,a}	5.69 ± 0.44 ^{**,a}
Group IV	65.69 ± 7.59 ^{***,a,b}	60.99 ± 5.25 ^{***,a,b}	157.81 ± 11.45 ^{***,a,b}	6.39 ± 0.52
Group V	46.57 ± 4.12	48.06 ± 1.85	116.43 ± 5.52	7.16 ± 0.70
Liver tissue				
Group I	11.07 ± 0.90	12.31 ± 1.50	5.02 ± 0.29	133.96 ± 5.73
Group II	6.63 ± 0.41 ^{***,a}	7.81 ± 1.24 ^{***,a}	3.62 ± 0.50 ^{***,a}	117.53 ± 6.63 ^{**,a}
Group III	6.61 ± 0.56 ^{***,a}	5.84 ± 0.75 ^{***,a}	3.97 ± 0.40 ^{***,a}	115.13 ± 14.2 ^{**,a}
Group IV	8.91 ± 1.41 ^{**,a,b}	9.98 ± 0.49 ^{*,a,b}	5.08 ± 0.67 ^{***,b}	124.20 ± 4.83
Group V	9.55 ± 0.43	12.33 ± 0.39	6.07 ± 0.30	135.08 ± 3.95

Values are mean ± S.D. of 6 rats. Groups II and III rats were sacrificed on day 22 and day 36, respectively. Serum and liver AST, ALT and ALP were expressed as IU/L and IU/g wet tissue, respectively. Protein in serum and liver tissue are expressed as mg/dL and mg/g wet tissue respectively.

^a Compared with Group I.
^b Compared with Group II.
^{*} $p < 0.05$.
^{**} $p < 0.01$.
^{***} $p < 0.001$.

3.3. Lipid peroxidation

Oxidative damage induced by DMN treatments (Groups II and III) is evidenced by more than two-fold increase in MDA formation in the liver tissue of rats (Fig. 1). Post-treatment of SBN after DMN treatment (Group IV) significantly prevented the formation of MDA and thus it exhibits its antioxidant effect against DMN-induced lipid peroxidation. SBN alone treatment (Group V) did not alter MDA level as compared to control.

3.4. SOD and CAT

Oxidative stress induced by DMN treatment (Group II) is further revealed by more than 50% fall in the activities ($p < 0.001$) of both SOD and CAT in the liver tissue. This adverse effect is mitigated in rats post-treated SBN after DMN intoxication (Group IV) indicating its protective role

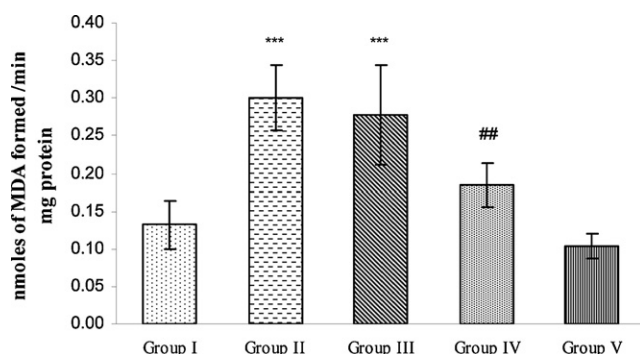


Fig. 1 – Lipid peroxidation (LPO) status in liver tissue of rats treated with DMN and SBN. Values are mean ± S.D. of 6 rats. Group II and Group III rats were sacrificed on days 22 and 36, respectively. *** $p < 0.001$ compared to Group I; ## $p < 0.01$ compared to Group II.

against DMN-induced oxidative stress. SBN alone treatment (Group V) did not cause any change in both the above parameters and they are comparable to saline treated control (Figs. 2 and 3).

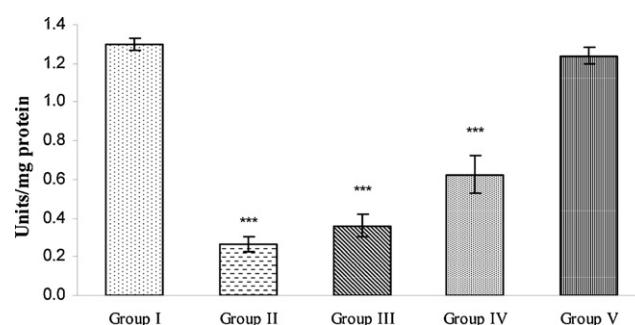


Fig. 2 – Status of SOD in liver tissue of rats treated with DMN and SBN. Values are mean ± S.D. of 6 rats. Group II and Group III rats were sacrificed in days 22 and 36, respectively. *** $p < 0.001$ compared to Group I.

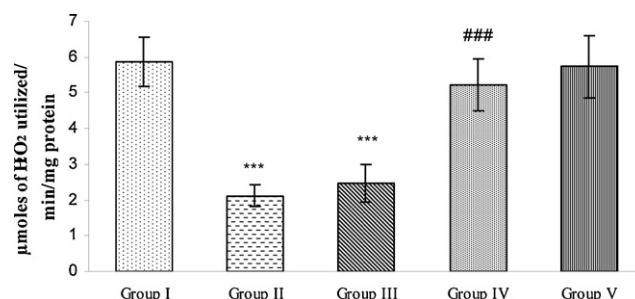


Fig. 3 – Status of catalase in liver tissue of rats treated with DMN and SBN. Values are mean ± S.D. of 6 rats. Group II and Group III rats were sacrificed in days 22 and 36, respectively. *** $p < 0.001$ compared to Group I; ### $p < 0.001$ compared to Group II.

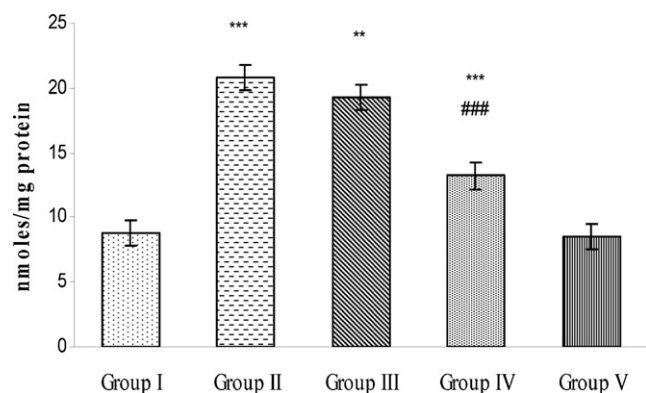


Fig. 4 – Protein carbonyls in liver tissue of rats treated with DMN and SBN. Values are mean \pm S.D. of 6 rats. Group II and Group III rats were sacrificed in days 22 and 36, respectively. ** $p < 0.01$, *** $p < 0.001$ compared to Group I; ### $p < 0.001$ compared with Group II.

3.5. Protein carbonyls

Protein carbonyls in liver tissue of DMN treated rats (Groups II and III) show a two-fold increase ($p < 0.001$) in its level as compared to saline treated control (Group I). This adversity was prevented and reversed back toward normalcy in rats post-treated SBN after DMN intoxication (Group IV). SBN alone treatment (Group V) did not alter protein carbonyl level and they were on par with control (Fig. 4).

3.6. ATPases

DMN intoxication (Groups II and III) produced highly significant decrease ($p < 0.001$) in the activities of Na^+/K^+ , Mg^{2+} and Ca^{2+} ATPases in the liver tissue of rats as compared to control (Group I), and this effect was significantly prevented and reversed back toward normalcy in rats treated DMN+SBN (Group IV). SBN alone treatment (Group V) did not produce any change in the activities of all the above ATPases and they were comparable to control (Fig. 5).

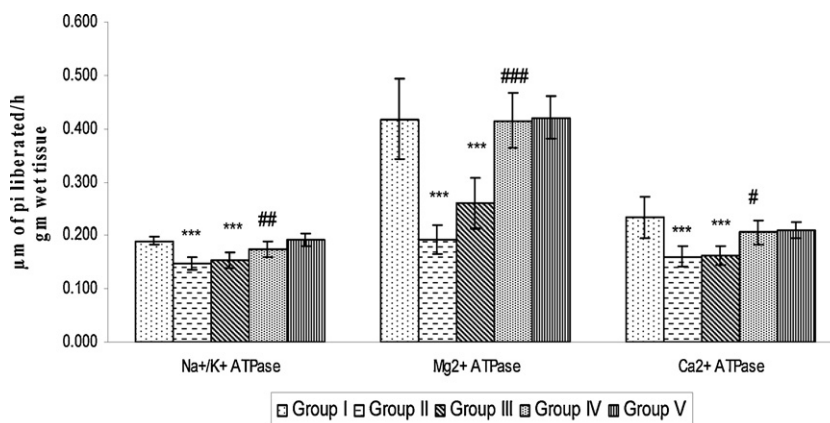


Fig. 5 – Activities of membrane bound ATPases (Na^+/K^+ , Mg^{2+} , Ca^{2+}) in liver tissue of rats treated with DMN and SBN. Values are mean \pm S.D. of 6 rats. Group II and Group III rats were sacrificed in days 22 and 36, respectively. *** $p < 0.001$ compared to Group I, # $p < 0.05$, ## $p < 0.01$, ### $p < 0.001$ compared to Group II.

3.7. Hydroxyproline and collagen

The liver hydroxyproline and collagen levels were increased significantly ($p < 0.001$) in DMN intoxicated rats (Groups II and III) when compared to saline treated control. Rats post-treated SBN, in DMN intoxicated rats (Group IV), exhibit significantly protection against the increase in the states of these parameters. SBN alone treatment did not show any change in liver hydroxyproline and collagen levels in the liver tissue as compared to saline treated control (Table 3).

3.8. Histopathology of liver tissue

The H & E stained rat liver cells of DMN treated rats (Groups II and III) show high degree of centrilobular necrosis and neutrophilic infiltration around this area. Bridging fibrosis could be seen between the portal triad and the central vein (Fig. 6). Masson's trichrome staining (which is specific indicator of deposition of extracellular matrix protein), shows intense bluish green staining of the liver tissue of DMN treated rats around portal vein, central vein and sinusoidal space (Fig. 7). These observations clearly demonstrate the deposition of extracellular matrix proteins in DMN-induced fibrotic rats. SBN post-treatment after DMN intoxication (Group IV) show noticeable reduction in hepatic necrosis, centrilobular neutrophilic infiltration and bridging fibrosis in H & E staining and marked reduction in the positive staining toward Masson's trichrome, indicating substantial reduction in hepatic fibrosis. SBN alone treatment (Group V) shows normal architecture of the liver (with normal centrilobular vein, radiating hepatocytes, portal triad, sinusoidal space) and are comparable to saline treated control.

4. Discussion

It is postulated that DMN treatment will induce inflammation of hepatocytes resulting in necrosis and it is indicated by an increase in marker enzymes of hepatotoxicity (AST, ALT, ALP) in the serum, accompanied by their fall in liver tissue (Priya et al., 2011a,b; Wang et al., 2010) and our results are in agreement with these reports. Transaminases and ALP are

Table 3 – Changes in hydroxyproline and collagen in rats treated with DMN and SBN.

Treatment groups	Parameters	
	Hydroxyproline ($\mu\text{g/g}$ wet tissue)	Collagen (mg/g wet tissue)
Group I	589.69 \pm 46.44	4.40 \pm 0.35
Group II	1384.60 \pm 138.13 ^{***,a}	11.57 \pm 1.46 ^{***,a}
Group III	1374.94 \pm 331.66 ^{***,a}	10.26 \pm 1.07 ^{***,a}
Group IV	959.14 \pm 78.31 ^{***,a,b}	7.16 \pm 0.58 ^{***,a,b}
Group V	524.58 \pm 51.90	4.71 \pm 0.34

Values are mean \pm S.D. of 6 rats. Groups II and III rats were sacrificed on days 22 and 36, respectively.

^a Compared with Group I.

^b Compared with Group II.

* $p < 0.05$.

** $p < 0.01$.

*** $p < 0.001$.

the sensitive indicators of hepatocellular injury and their elevation is said to occur consequent to necrosis of hepatocytes, leading to their leakage into serum during toxins induced liver injury (Sallie et al., 1991). Liver injury, marked as centrilobular necrosis and neutrophilic infiltration around centrilobular area could be seen in H & E stained rat liver cells which are exposed to intermittent DMN and thus, the biochemical studies are well corroborated with the histopathological observations.

The fall in liver weight, body weight and their ratio accompanied by fall in liver protein observed in DMN treated rats are in acceptance with the previous reports (Hsu et al., 2007; George and Chandrakasan, 1996). The decrease in the above parameters could be attributed to the reduction in protein synthesis, cell necrosis and collapse of parenchymal cells (George and Chandrakasan, 1996; Ala-Kokko et al., 1987). Though, there seems to be net synthesis of proteins, which is said to occur due to the proliferation of Ito cells during DMN-induced hepatic fibrosis (George et al., 2001; Gressner, 1995; Weiner et al., 1992), there is an apparent decrease of protein in the liver and this adversity could be due to the true decrease in absolute amount of total liver protein (George et al., 2001). In the present study, the fall in the of protein levels observed in the liver and serum of DMN treated rats could be attributed to the inhibition of protein synthesis as being proposed by previous workers (George et al., 2001; Heath, 1962; Magee, 1958).

There exists convincing evidence to support the contention that oxidative stress and liberation of reactive oxygen species (ROS) play vital role in the etiology and progression of liver fibrosis (Poli, 2000; Shimizu et al., 1999). Oxidative stress, marked as elevation in the status of malondialdehyde and protein carbonyls have been reported in DMN treated rats and our results are in agreement with these reports (Priya et al., 2011a; Tahan et al., 2004). It is hypothesized that the free radicals generated by DMN during its metabolism in the liver reacts with the poly unsaturated fatty acids of hepatic microsomal systems and cause rearrangement of the double bonds to generate diene conjugated lipids and there by enhance oxidative stress (George, 2003). In addition, free radical induced damage to proteins has been implicated as cause for oxidative stress. It is said that carbonyl (Co) groups (aldehydes and ketones) are produced on protein side chains (especially of proline, argentine, lysine and threonine) during oxidative stress (Isabella Dalle-donne, 2003) and this could be the

possible cause for elevation of protein carbonyls observed in DMN treated rats.

In the present study, oxidative stress induced by DMN treatment is also demonstrated by a highly significant fall in the activities of SOD and CAT and our results are in agreement with previous reports (Priya et al., 2011a,b; Wang et al., 2010; Hong et al., 2010). The decrease in the activities of these enzymes could possibly be due to their over utilization toward suppression of reactive oxygen species that are liberated during metabolism of DMN in the liver. The cause for the onset of hepatic fibrosis and its relationship with oxidative stress is not well defined. However, it is hypothesized that the ROS scavenging systems are mainly present in the hepatocytes or they are compartmentalized in specific organelles like peroxisomes (CAT) and mitochondria (Mn SOD) and hence, they will not prevent the HSCs that are present in the space of Disse, outside the hepatocytes, from being exposed to ROS generated by inflammatory infiltrating cells, and this could be the cause for the excessive ROS production and activation of HSCs play a pivot role in the onset and progression of hepatic fibrosis in DMN treated rats (Hong et al., 2010; O'Brien, 1984).

Oxidative stress causes peroxidative damage of the lipid membrane is said to alter the structural and functional characteristics of liver parenchymal cell membrane and it is reported to be manifested as changes in the activities of membrane bound ATPase (Freel and Goldner, 1981). The fall in the activities of Na^+/K^+ , Mg^{2+} and Ca^{2+} ATPases observed in the liver tissues of DMN treated rats is an indication to demonstrate the disruption of hepatocellular membrane integrity. These enzymes are responsible for transport of ions across cell membranes at the expense of ATP (Vasudevan and Sreekumari, 2001; Murray et al., 2003) and are extremely sensitive to hydroperoxides and superoxide radicals (Jain and Shohet, 1981). The fall in the activities of these enzymes in the liver tissue is an additional proof for DMN-induced oxidative stress and free radical damage to the hepatocytes and their cellular membrane integrity.

Accumulation of connective tissue proteins, especially collagen and hydroxyproline has been reported in DMN induced fibrotic rats and measurement of these parameters is suggested as a valuable tool in the quantification of fibrosis as well as assessment of potency of anti-fibrotic drugs during therapeutic trials (Yuan et al., 2004; Kusunose et al., 2002). In the present study, repeated administration of DMN caused

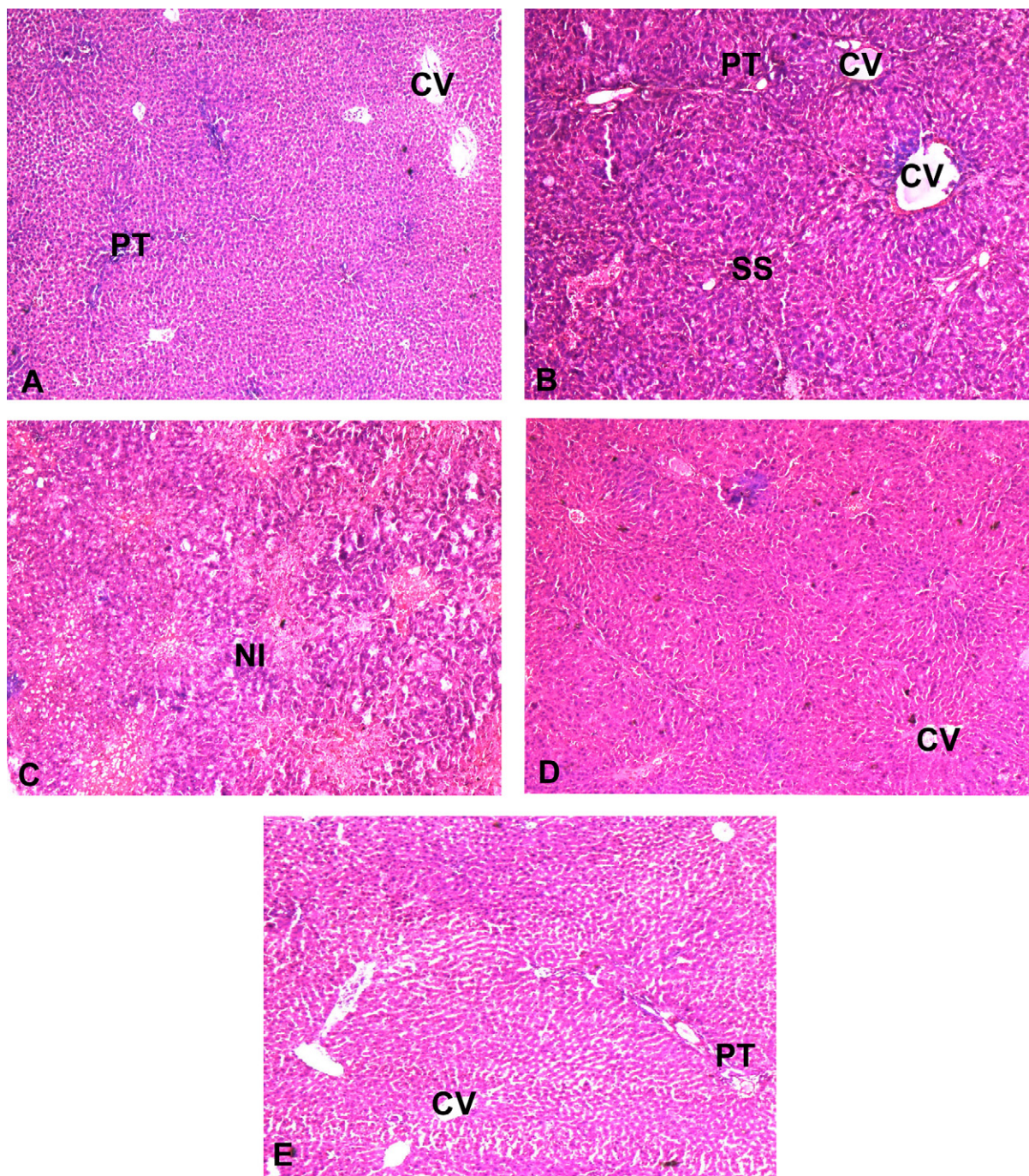


Fig. 6 – (A) Group I (saline treated control) shows normal liver architecture with radiating hepatocytes around central vein (CV), portal triad (PT) and normal sinusoidal space (SS). **(B)** Group II rats show dilated central vein with inflammatory and fibrotic changes. **(C)** Group III rats show severe congestion with neutrophilic infiltration (NI) and disruption of normal liver architecture and bridging fibrosis. **(D)** Group IV (DMN + SBN) rats shows normal central vein with mild neutrophilic infiltration around portal triad. There is considerable reduction in hepatic fibrosis. **(E)** Group V (SBN alone treated) rats shows normal architecture of liver compared to Group I.

an increase in hydroxyproline and collagen in the liver tissue, indicating establishment of hepatic fibrosis and our results are in agreement with previous reports (George et al., 2001; George and Chandrakasan, 1997). Hepatic fibrosis induced by DMN is well demonstrated in the Masson's trichrome staining as well as in H & E stained histopathological studies of DMN

treated rats as fibrosis and deposition of fibrous proteins in the sinusoidal space.

In the present investigation, amelioration of DMN-induced hepatic fibrosis, inflammatory changes and hepatic necrosis is well evidenced in rats post-treated with SBN after DMN intoxication. This beneficial effect is shown by reversal of AST,

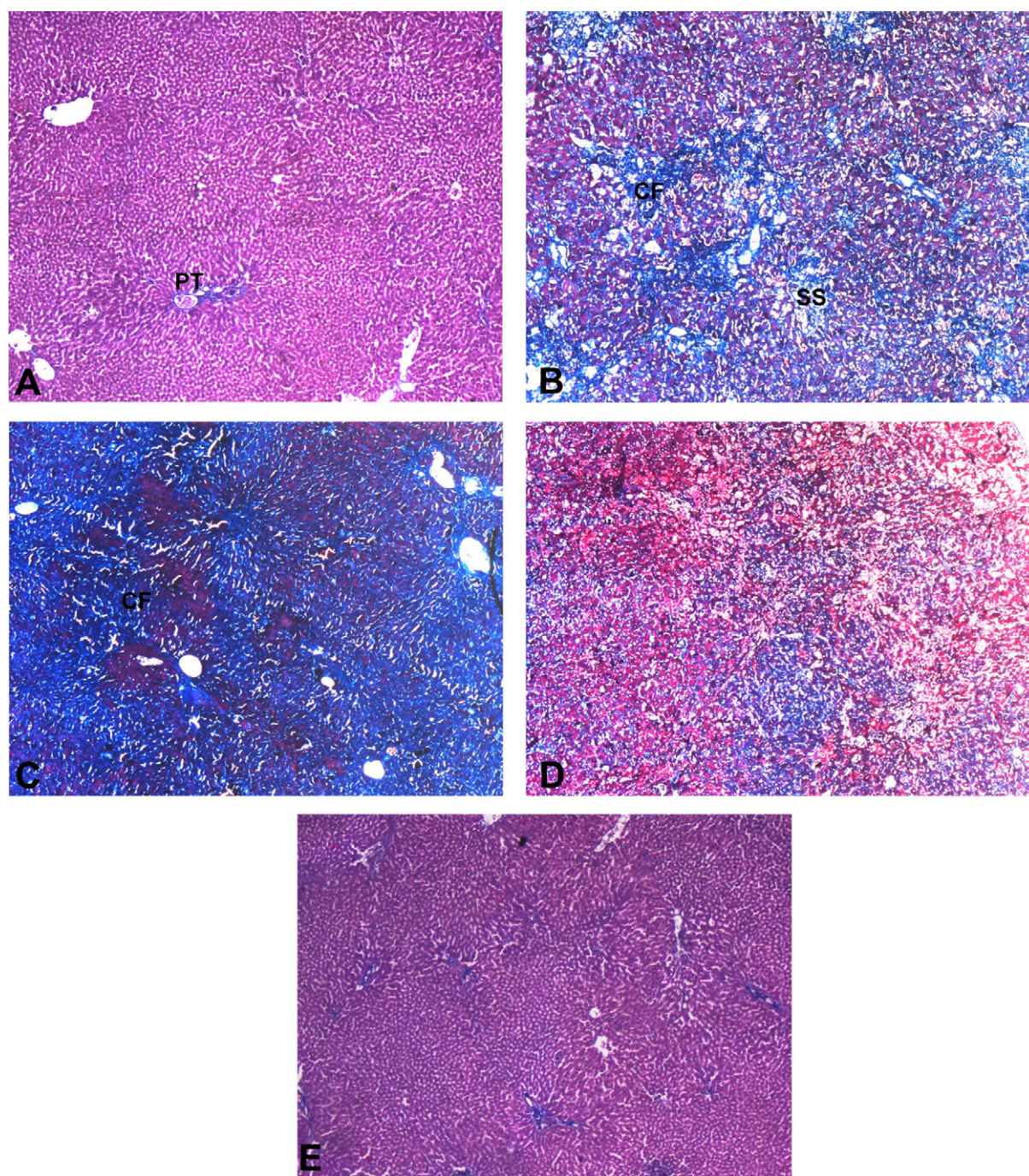


Fig. 7 – (A) Group I Masson's trichrome positive staining is present around portal triad area only. (B) Group II bluish green patches indicate Masson's trichrome positive staining which shows accumulation of collagen fiber (CF) in the sinusoidal space. (C) Group III rat liver shows intense and more pronounced Masson's trichrome positive staining indicating more deposition of collagen fiber. (D) Group IV the lesser intensity of bluish green patches in this treatment indicates less deposition of collagen fiber. (E) Group V shows normal architecture of liver comparable to Group I. (For interpretation of the references to color in this figure legend, the reader is referred to the web version of the article.)

ALT, ALP, protein LPO, SOD, CAT, protein carbonyls, hydroxyproline, collagen and membrane bound ATPases in both the serum and/or liver tissues of rats treated DMN and SBN. This protective effect of SBN post-treatment against hepatic necrosis, inflammatory changes and hepatic fibrosis induced by DMN treatment, also shown by both H & E and Masson's

trichrome stained histopathological evaluation of liver cells. Several studies have shown the protective role of SBN by way of its free radical scavenging and antioxidant properties (Gazak et al., 2007; Valenzuela et al., 1985).

It is said that *Silybum marianum* extract (which is rich in SBN) is membranotropic in nature and it has been shown

to bind tightly to hepatocellular membrane (Ramellini and Meldolesi, 1974). Further, the interaction of silimarin and SBN with polar head group of phospholipids at the lipid–water interface of the cellular membrane, and their counteraction of lipid-peroxidation are said to be the major causes for these bioflavonoids to act as excellent protective against lipid peroxidation and breakdown of membrane integrity against free radical induced peroxidative damage on cellular membrane (Erlejman et al., 2004; Muriel et al., 1992). Thus, the observation of reversal toward the fall in the status of membrane APTases and that of the enzymic and non-enzymic antioxidants (LPO, SOD, CAT) by SBN in DMN treated rats could be attributed to the protection of hepatocellular membrane integrity by hydrogen bonding of SBN to polar head groups of phospholipids present in hepatocellular membrane and this interaction could have prevented the access of DMN-induced reactive oxygen species metabolites. Further, this interaction could have also resulted in counteracting lipid peroxidation, by way of antioxidant and free radical scavenging properties of SBN.

The Nuclear Factor kappa (NF- κ B) is a ubiquitous rapid response transcription factor, commonly expressed during cellular injury and inflammation induced by various toxic agents (Saliou et al., 1998). It is reported previously that NF- κ B shows higher expression during HSCs activation following oxidative stress induced by hepatic fibrosis and inflammation (Elsharkawy et al., 1999). Administration of certain pharmacological antioxidant agents can inhibit the activation of NF- κ B. Silimarin treatment was found to suppress both kappaB motif of NF- κ B DNA binding activity and its gene expression in hepatic cells. In addition, it blocks translocation of NF- κ B, p65 protein (through phosphorylation) to the nucleus without affecting its ability to bind to DNA (Manna et al., 1999). In view of these reports, it could be suggested that ameliorative property of SBN post-treatment against DMN-induced hepatic necrosis and fibrosis could be due to its ability to suppress NF- κ B activity.

In conclusion, our present results demonstrate that post-treatment of SBN protects liver against DMN-induced hepatic necrosis, inflammatory changes and hepatic fibrosis by way of its antioxidant, free radical scavenging, membrane stabilizing and by suppression of fibrosis. However, further studies are warranted to explore the therapeutic efficacy and mechanism of anti-fibrotic activity of SBN.

Conflict of interest statement

The authors declare that there are no conflicts of interest.

Acknowledgements

This study was financially supported by the Department of Science and Technology, New Delhi, Government of India in the form of INSPIRE fellowship (award letter no.: DST/INSPIRE Fellowship/2010/dated 16.03.2010) and also authors wish to thank University of Madras for providing financial assistance in the form of University Research Fellowship.

REFERENCES

- Ala-Kokko, L., Pihlajaniemi, T., Myers, J.C., Kivirikko, K.I., Savolainen, E.R., 1987. Gene expression of type I, III and IV collagens in hepatic fibrosis induced by dimethylnitrosamine in the rat. *Biochem. J.* 244, 75–79.
- Bancroft, J.D., Cook, B.C., 1984. *Manual of Histological Techniques*. Churchill Livingstone, Edinburgh, pp. 49–51.
- Du, W.D., Zhang, Y., Zhai, W.R., Zhou, X.M., 1999. Dynamic changes of type I, III and IV collagen synthesis and distribution of collagen-producing cells in carbon tetrachloride-induced rat liver fibrosis. *World J. Gastroenterol.* 5 (5), 397–403.
- Elsharkawy, A.M., Wright, M.C., Hay, R.T., Arthur, M.J., Hughes, T., Bahr, M.J., Degitz, K., Mann, D.A., 1999. Persistent activation of nuclear factor- κ B in cultured rat hepatic stellate cells involves the induction of potentially novel Rel-like factors and prolonged changes in the expression of I κ B family proteins. *Hepatology* 30, 761–769.
- Erlejman, A.G., Verstraeten, S.V., Fraga, C.G., Oteiza, P.I., 2004. The interaction of flavonoids with membranes: potential determinant of flavonoid antioxidant effects. *Free Radic. Res.* 38 (12), 1311–1320.
- Fiske, C.H., Subbarow, Y., 1925. The colorimetric determination of phosphorous. *J. Biol. Chem.* 66, 375–400.
- Freel, R.W., Goldner, A.M., 1981. Sodium coupled-electrolyte transport across epithelial layer: emerging concepts and directions. *Am. J. Physiol.* 241, G451–G460.
- Friedman, S.L., 1993. The cellular basis of hepatic fibrosis: mechanism and treatment strategies. *N. Engl. J. Med.* 328, 1828–1835.
- Gazak, R., Walterova, D., Kren, V., 2007. Silybin and silymarin—new and emerging applications in medicine. *Curr. Med. Chem.* 14, 315–338.
- George, J., 2003. Ascorbic acid concentrations in dimethylnitrosamine-induced hepatic fibrosis in rats. *Clin. Chim. Acta* 335, 39–47.
- George, J., Chandrakasan, G., 1996. Molecular characteristics of dimethylnitrosamine induced fibrotic liver collagen. *Biochim. Biophys. Acta* 1292, 215–222.
- George, J., Chandrakasan, G., 1997. Lactate dehydrogenase isoenzymes in dimethylnitrosamine induced hepatic fibrosis in rats. *J. Clin. Biochem. Nutr.* 22, 51–62.
- George, J., Rao, K.R., Stern, R., Chandrakasan, G., 2001. Dimethylnitrosamine-induced liver injury in rats: the early deposition of collagen. *Toxicology* 156, 129–138.
- Gressner, A.M., 1995. Cytokines and cellular crosstalk involved in the activation of fat-storing cells. *J. Hepatol.* 22, S28–S36.
- Harrison Immanuel, S., Ezhilarasan, D., Vivekanandan, P., Emmannvel Rajan, E., Karthikeyan, S., 2010. Influence of silybinin on N-nitrosodimethylamine-induced changes in the genomic DNA and protein expression in the live and lung tissue of rats. *Biomedicine* 30 (3), 346–352.
- Heath, D.F., 1962. The decomposition and toxicity of dialkyl nitrosamines in rats. *Biochem. J.* 85, 72–91.
- Hjerten, S., Pan, H., 1983. Purification and characterization of two forms of a low affinity Ca²⁺ ATPase from erythrocyte membranes. *Biochim. Biophys. Acta* 728, 281–288.
- Hong, S.W., Jung, K.H., Zheng, H.M., Lee, H.S., Suh, J.K., Park, I.S., Lee, D.H., Hong, S.S., 2010. The protective effect of resveratrol on dimethylnitrosamine-induced liver fibrosis in rats. *Arch. Pharm. Res.* 33 (4), 601–609.
- Hsu, Y.C., Chiu, Y.T., Cheng, C.C., Wu, C.F., Lin, Y.L., Huang, Y.T., 2007. Antifibrotic effects of tetrandrine on hepatic stellate cells and rats with liver fibrosis. *J. Gastroenterol. Hepatol.* 22, 99–111.

- Isabella Dalle-donne, 2003. Protein carbonyl groups as biomarkers of oxidative stress. Review. Clin. Chim. Acta 329, 23–38.
- Jain, S.K., Shohet, S.B., 1981. Calcium potentiates the peroxidation of erythrocyte membrane lipids. Biochim. Biophys. Acta 642, 46–54.
- Jézéquel, A.M., Mancini, R., Rinaldesi, M.L., Ballardini, G., Fallani, M., Bianchi, F., Orlandi, F., 1989. Dimethylnitrosamine induced cirrhosis. Evidence for an immunological mechanism. J. Hepatol. 8, 42–52.
- King, J., 1965. The phosphohydrolases—acid and alkaline phosphatases. In: Practical Clinical Enzymology. D. Van Nostrand Co Ltd., London, pp. 191–208.
- Kusunose, M., Qiu, B., Cui, T., Hamada, A., Yoshioka, S., Ono, M., Miyamura, M., Kyotani, S., Nishioka, Y., 2002. Effect of Sho-saiko-to extract on hepatic inflammation and fibrosis in dimethylnitrosamine induced liver injury in rats. Biol. Pharm. Bull. 25, 1417–1421.
- Levine, R.L., Garland, D., Oliver, C.N., Amici, A., Climent, I., Lenz, A.G., Ahn, B.W., Shaltiel, S., Stadtman, E.R., 1990. Determination of Carbonyl content in oxidatively modified proteins. Methods Enzymol. 186, 464–478.
- Lowry, O.H., Rosebrough, N.J., Farr, A.L., Randall, R.J., 1951. Protein measurement with the Folin phenol reagent. J. Biol. Chem. 193, 265–275.
- Magee, P.N., 1958. Toxic liver injury; inhibition of protein synthesis in rat liver by dimethylnitrosamine in vivo. Biochimica 70, 606–611.
- Manna, S.K., Mukhopadhyay, A., Van, N.T., Aggarwal, B.B., 1999. Silymarin suppresses TNF-induced activation of NF-kappa B, c-Jun N-terminal kinase, and apoptosis. J. Immunol. 163, 6800–6809.
- Marklund, S., Marklund, G., 1974. Involvement of the superoxide anion radical in the autooxidation of pyrogallol and a convenient assay for superoxide dismutase. Eur. J. Biochem. 47, 469–474.
- Muriel, P., Garciapina, T., Perez-Alvarez, V., Mourelle, M., 1992. Silymarin protects against paracetamol-induced lipid peroxidation and liver damage. J. Appl. Toxicol. 12, 439–442.
- Murray, R.K., Granner, D.K., Mayes, P.A., Rodwell, V.W., 2003. Harper's Illustrated Biochemistry, 26th ed. The McGraw-Hill Companies Inc., USA.
- Neuman, R.E., Logan, M.A., 1950b. The determination of collagen and elastin in tissues. J. Biol. Chem. 186, 549–556.
- Neuman, R.E., Logan, M.A., 1950a. The determination of hydroxyproline. J. Biol. Chem. 184, 299–306.
- O'Brien, P.J., 1984. Superoxide production. Methods Enzymol. 105, 370–378.
- Ohkawa, H., Ohishi, N., Yagi, K., 1979. Assay for lipid peroxides in animal tissues by thiobarbituric acid reaction. Anal. Biochem. 95, 351–358.
- Ohnishi, T., Suzuki, T., Suzuki, Y., Ozawa, K., 1982. A comparative study of plasma membrane Mg²⁺ ATPase activities in normal, regenerating and malignant cells. Biochim. Biophys. Acta 684, 67–74.
- Poli, G., 2000. Pathogenesis of liver fibrosis: role of oxidative stress. Mol. Aspects Med. 21, 49–98.
- Priya, S., Vijayalakshmi, P., Vivekanandan, P., Karthikeyan, S., 2011a. N-Acetylcysteine attenuates dimethylnitrosamine induced oxidative stress in rats. Eur. J. Pharmacol. 654, 181–186.
- Priya, S., Vijayalakshmi, P., Vivekanandan, P., Karthikeyan, S., 2011b. Influence of N-acetylcysteine against dimethylnitrosamine induced hepatotoxicity in rats. Toxicol. Ind. Health 27 (10), 914–922.
- Ramellini, G., Meldolesi, J., 1974. Stabilization of isolated rat liver plasma membranes by treatment in vitro with silymarin. Arzneimittelforschung. 24 (5), 806–808.
- Reitman, S., Frankel, S., 1957. A colorimetric method for the determination of serum glutamic oxaloacetate and glutamic pyruvic transaminases. Am. J. Clin. Pathol. 28, 56–63.
- Saliou, C., Rihn, B., Cillard, J., Okamoto, T., Packer, L., 1998. Selective inhibition of NF-kappa B activation by the flavonoid hepatoprotector silymarin in HepG2, evidence for different activating pathways. FEBS Lett. 440, 8–12.
- Sallie, R., Trdeger, J.J., William, R., 1991. Drugs and the liver. Biopharm. Drug Dispos. 12, 251–259.
- Shimizu, I., Ma, Y.R., Mizobuchi, Y., Liu, F., Miura, T., Nakai, Y., Yasuda, M., Shiba, M., Horie, T., Amagaya, S., Kawada, N., Hori, H., Ito, S., 1999. Effects of sho-saiko-to, a Japanese herbal medicine, on hepatic fibrosis in rats. Hepatology 29, 149–160.
- Sinha, A.K., 1972. Colorimetric assay of catalase. Anal. Biochem. 47, 389–394.
- Tahan, V., Ozaras, R., Canbakan, B., Uzun, H., Aydin, S., Yildirim, B., Aytekin, H., Ozbay, G., Mert, A., Senturk, H., 2004. Melatonin reduces dimethylnitrosamine-induced liver fibrosis in rats. Pineal. Res. 37 (2), 78–84.
- Valenzuela, A., Lagos, C., Schmidt, K., 1985. Silymarin protection against hepatic lipid peroxidation induced by acute ethanol intoxication in the rat. Biochem. Pharmacol. 34, 2209–2212.
- Vasudevan, D.M., Sreekumari, S., 2001. Text Book of Biochemistry for Medical Students, 3rd ed. Jaypee Brothers Medical Publishers (P) Ltd., New Delhi.
- Vendemiale, G., Grattagliano, I., Caruso, M.L., Serviddio, G., Valentini, A.M., Pirrelli, M., Altomare, E., 2001. Increased oxidative stress in dimethylnitrosamine-induced liver fibrosis in the rat: effect of N-acetylcysteine and interferon-alpha. Toxicol. Appl. Pharmacol. 175, 130–139.
- Wang, J.H., Shin, J.W., Son, J.Y., Cho, J.H., Son, C.G., 2010. Antifibrotic effects of CGX, a traditional herbal formula, and its mechanisms in rats. J. Ethnopharmacol. 127, 534–542.
- Weiner, F.R., Shah, A., Biempica, L., Zern, M.A., Czaja, M.J., 1992. The effects of hepatic fibrosis on Ito cell gene expression. Matrix 12, 36–43.
- Yuan, G.J., Zhang, M.L., Gong, Z.J., 2004. Effect of PPARγ agonist pioglitazone on rat hepatic fibrosis. World J. Gastroenterol. 10, 1047–1051.