



Pterostilbene inhibits dimethylnitrosamine-induced liver fibrosis in rats

Ming-Fen Lee^a, Min-Lung Liu^b, An-Chin Cheng^a, Mei-Ling Tsai^b, Chi-Tang Ho^c, Wen-Shiung Liou^{d,*},
Min-Hsiung Pan^{b,*}

^a Department of Nutrition and Health Sciences, Chang Jung Christian University, Tainan 71101, Taiwan, ROC

^b Department of Seafood Science, National Kaohsiung Marine University, Kaohsiung 81157, Taiwan, ROC

^c Department of Food Science, Rutgers University, New Brunswick, NJ 08901-8520, USA

^d Department of Obstetrics and Gynecology, Kaohsiung Veterans General Hospital, Taiwan, ROC

ARTICLE INFO

Article history:

Received 4 September 2012

Received in revised form 26 October 2012

Accepted 22 November 2012

Available online 1 December 2012

Keywords:

Collagen

Dimethylnitrosamine

Hepatic stellate cells

Liver fibrosis

Matrix metalloproteinase 2

Pterostilbene

Smooth muscle actin

Transforming growth factor- β 1

ABSTRACT

Pterostilbene, found in grapes and berries, exhibits pleiotropic effects, including anti-inflammatory, antioxidant, and anti-proliferative activities. This study was conducted to investigate the effect of pterostilbene on liver fibrosis and the potential underlying mechanism for such effect. Sprague–Dawley rats were intraperitoneally given dimethyl n-nitrosamine (DMN) (10 mg/kg) 3 days per week for 4 weeks. Pterostilbene (10 or 20 mg/kg) was administered by oral gavage daily. Liver function, morphology, histochemistry, and fibrotic parameters were examined. Pterostilbene supplementation alleviated the DMN-induced changes in the serum levels of alanine transaminase and aspartate transaminase ($p < 0.05$). Fibrotic status and the activation of hepatic stellate cells were improved upon pterostilbene supplementation as evidenced by histopathological examination as well as the expression of α -smooth muscle actin (α -SMA), transforming growth factor- β 1 (TGF- β 1), and matrix metalloproteinase 2 (MMP2). These data demonstrated that pterostilbene exhibited hepatoprotective effects on experimental fibrosis, potentially by inhibiting the TGF- β 1/Smad signaling.

© 2012 Elsevier Ltd. All rights reserved.

1. Introduction

Stilbene phytoalexins, such as resveratrol (*trans*-3,4',5-trihydroxystilbene) and its natural dimethylether analogue, pterostilbene (*trans*-3,5-dimethoxy-4'-hydroxystilbene), are plant's defense means in response to environmental stresses, including microbial infection and ultraviolet radiation (Adrian, Jeandet, Douillet-Breuil, Tesson, & Bessis, 2000; Douillet-Breuil, Jeandet, Adrian, & Bessis, 1999). We and others have shown that pterostilbene, mainly from blueberries and grape vines (Szajdek & Borowska, 2008), exhibits pleiotropic pharmacological effects including anti-inflammatory, antioxidant, anti-proliferative, anti-cancer, and pain-relieving activities in cell culture and animal studies (Chiou et al., 2010; Pan et al., 2009; Remsberg et al., 2008). The potential chemopreventive and therapeutic effects of resveratrol in hepatocarcinogenesis has been reviewed (Mann et al., 2009); however, the effect of pterostilbene on earlier stages of liver injury such as fibrosis and cirrhosis has not been studied extensively.

When suffering from chronic injury, liver undergoes wound-healing processes, accumulate extracellular matrix proteins, and consequently, fibrosis or scarring ensues. Multiple etiologies, including viral hepatitis, alcohol intoxication, drug abuse, metabolic disorders due to mineral overload, and autoimmune diseases, attribute to liver fibrosis (Friedman, 2003; Kisseleva & Brenner, 2006), which may further evolve into cirrhosis. Liver cirrhosis often results in high mortality (Friedman, 2003) and is also a risk factor in the development of hepatocellular carcinoma (HCC) (Battaller & Brenner, 2005), which ranks the fifth of the cancer incidence worldwide (Caldwell & Park, 2009).

Hepatic stellate cells (HSC; also known as Ito cells or lipocytes) are involved in the fibrogenesis. During liver injury, hepatic stellate cells switch from quiescent, vitamin A-storing epithelial features to activated, vitamin A-losing and α -smooth muscle actin (α -SMA)-expressing myofibroblastic phenotypes (Friedman, 2008b; Gressner, Weiskirchen, & Gressner, 2007). Alpha-smooth muscle actin has been shown as a fairly reliable marker of the activation of the HSC in both experimental and clinical settings (Moreira, 2007). In addition to the morphological changes, HSC also produce excessive extracellular matrix proteins, including, and in particular, collagen type I, (Friedman, 2008a). A wide range of cell types, including hepatocytes and Kupffer cells, in liver, and cytokines such as platelet-derived growth factor (PDGF) and transforming

* Corresponding authors. Address: Department of Seafood Science, National Kaohsiung Marine University, No. 142, Haijhuang Rd., Nanzih District, Kaohsiung 81143, Taiwan, ROC. Tel.: +886 7 361 7141x3623; fax: +886 7 361 1261 (M.-H. Pan).
E-mail address: mhpan@mail.nkmu.edu.tw (M.-H. Pan).

growth factor-beta (TGF- β), play important roles during the process of liver injury (Kisseleva & Brenner, 2006; Moreira, 2007). Previously, liver fibrosis and cirrhosis were presumed irreversible responses whereas current thoughts hold otherwise, if the underlying etiology is eradicated (Rossi, Adams, Bulsara, & Jeffrey, 2007; Zhou & Lu, 2009). Therefore, establishing effective anti-fibrotic strategies could ultimately manage liver fibrosis and cirrhosis and provide favourable prognosis for chronic liver diseases (Friedman, 2003).

Dimethyl n-nitrosamine (DMN) is a potent hepatotoxin, which is metabolised by microsomal cytochrome p450IIE1 in liver (Yang, Tu, Koop, & Coon, 1985; Yoo, Guengerich, & Yang, 1988). Administration of DMN can induce liver damage in rats, which mimics the progression of liver fibrosis and cirrhosis in humans (George, Rao, Stern, & Chandrakasan, 2001). Therefore, DMN-treated animal models are widely used to study the biochemical and pathological manifestations of liver injury (Ala-Kokko, Pihlajaniemi, Myers, Kivirikko, & Savolainen, 1987; George & Chandrakasan, 1996; George et al., 2001).

In this study, we investigated the effect of pterostilbene on a well-characterised animal model of DMN-induced liver fibrosis. We found that pterostilbene improved serum parameters of liver function, inhibited the activation of HSC, reduced the expression of α -SMA and collagen I, and alleviated the progression of liver injury, potentially by inhibiting the TGF- β 1/Smad-mediated signaling.

2. Materials and methods

2.1. Reagents and chemicals

Pterostilbene was synthesised as described previously (Pan et al., 2009). All reagents and chemicals were purchased from Sigma, Inc. (St. Louis, MO) unless specified otherwise. N-Nitrosodimethylamine (dimethyl n-nitrosamine; DMN) was purchased from Wako Pure Chemical Industries Ltd. (Osaka, Japan). Alpha-SMA and matrix metalloproteinase 2 (MMP2) antibodies were obtained from Epitomics, Inc. (Burlingame, CA). Beta-actin antibody was obtained from Santa Cruz Biotechnology (Santa Cruz, CA). TGF- β 1, p-Smad2, p-Smad3, and Smad2/3 antibodies were purchased from Transduction Laboratories (BD Biosciences, Lexington, KY).

2.2. Animals and treatment

Thirty-two male Sprague–Dawley rats, weighing 200–250 g, were purchased from the National Laboratory Animal Center (Taipei, Taiwan). All animal experimental protocols used in this study were approved by Institutional Animal Care and Use Committee of the National Kaohsiung Marine University (IACUC, NKMU). The animals were housed in a humidity-controlled room at $25 \pm 1^\circ\text{C}$ with a 12-h dark/light cycle with free access to Laboratory rodent diet 5001 (PMI Nutritional International, Brentwood, MO) and water. After 2-week of acclimation, the animals were randomly assigned into three DMN-treated groups and one control group with eight rats in each group. The DMN-treated animals were administered DMN (10 mg per kg body weight) via intraperitoneal (i.p.) injection on Monday, Wed, and Friday for four consecutive weeks. Control, untreated animals were given an equal volume of normal saline. Two DMN groups were also administered 10 mg and 20 mg pterostilbene per kg body weight, respectively, by oral gavage daily.

At the end of the study period, all animals were killed under CO₂ anesthesia. Blood was collected by cardiac puncture and serum was harvested and stored at -80°C until analysis. After rinsing with normal saline, the weights of livers, spleens, and kidneys were

recorded. The liver samples were either immediately frozen in liquid nitrogen and kept at -80°C for further analysis or fixed with 10% buffered neutral formalin and embedded in paraffin for histological examination. Liver tissue sections (5 μm thickness) were subjected to Sirius red and immunohistochemistry staining methods for collagen distribution and α -SMA expression, respectively.

2.3. Biochemical analysis of liver function

Liver function was assessed by the serum levels of aspartate transaminase (AST), alanine transaminase (ALT), triacylglycerol (TG), and total cholesterol (T-chol). Briefly, serum was spotted onto respective Fujifilm Dri-Chem slides (Fujifilm, Kanagawa, Japan) and each biochemical indicator was determined using a blood biochemistry analyzer (Fujifilm Dri-Chem 3500s; Fujifilm, Kanagawa, Japan) according to the manufacturer's instructions.

2.4. Tissue protein extraction, Western blot analysis, and detection

Liver tissues were homogenised and total proteins were extracted using gold lysis buffer (20 mM Tris-HCl, pH 7.4; 1 mM NaF; 150 mM NaCl; 1 mM ethylene glycol tetraacetic acid (EGTA); 1 mM phenylmethanesulphonyl fluoride; 1% NP-40; and 10 $\mu\text{g}/\text{mL}$ leupeptin). Protein concentrations were measured by Bio-Rad protein assay (Bio-Rad Laboratories, Munich, Germany). Fifty micrograms of protein were mixed with 5 \times sample buffer (0.3 M Tris-HCl (pH 6.8), 25% 2-mercaptoethanol, 12% sodium dodecyl sulphate (SDS), 25 mM EDTA, 20% glycerol, and 0.1% bromophenol blue), subjected to 10% SDS-polyacrylamide gel electrophoresis, and electrotransferred onto immobile membranes (PVDF; Millipore Corp., Bedford, MA). The membranes were immunoblotted with primary antibodies including α -SMA, MMP2, TGF- β 1, p-Smad2, p-Smad3, and Smad2/3, and β -actin (Transduction Laboratories, BD Biosciences, Lexington, KY) at room temperature for 1 h. Detection was achieved by measuring the chemiluminescence of blotting agent (ECL, Amersham Corp., Arlington Heights, IL) and analyzed by densitometric scanning (Alliance 4.7, UVItec, Cambridge, UK).

2.5. Statistical analysis

All data were expressed as mean \pm SD. All statistical analyses were performed by Student's *t* test using Sigma Plot 10.0. A value of $p < 0.05$ was considered statistically significant.

3. Results

3.1. Effect of pterostilbene on the relative organ weights of the DMN-treated rats

The average body weight of the three DMN-treated groups was significantly lower than that of the control group at the end of the study, whereas no significant difference was observed among the DMN-treated animals with or without pterostilbene supplementation (Fig. 1). In the DMN-alone group, the weight of liver was significantly lower than that of the control group, whereas the weights of kidney and spleen were significantly higher than those of the control group (Table 1). Pterostilbene supplementation (20 mg/kg body weight) significantly attenuated the changes in weights of liver, kidney, and spleen caused by DMN treatment (Table 1).

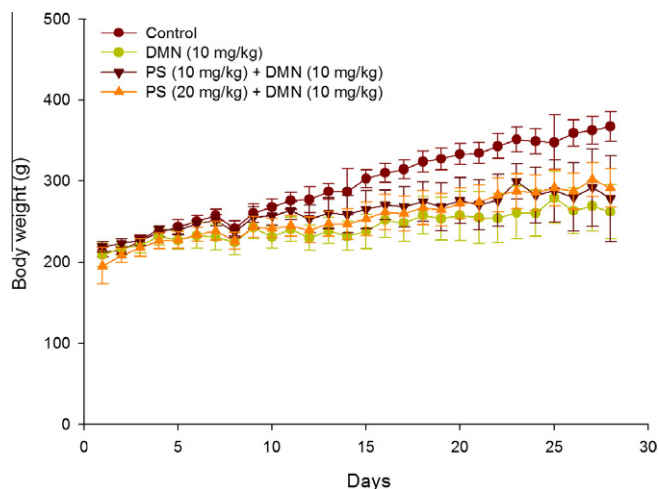


Fig. 1. Body weight of the experimental animals. DMN was given intraperitoneally at a dose of 10 mg/kg body weight on every Monday, Wednesday, and Friday for four consecutive weeks to each group except the control group. DMN (10 mg/kg), DMN alone; pterostilbene (PS) (10 mg/kg) + DMN (10 mg/kg), DMN with 10 mg/kg pterostilbene supplementation by oral gavage daily; PS (20 mg/kg) + DMN (10 mg/kg), DMN with 20 mg/kg pterostilbene supplementation by oral gavage daily. Body weight was recorded daily.

Table 1
Effect of pterostilbene (PS) on the relative organ weights of the DMN-treated rats.

Groups	Relative organ weight (g/of body weight)		
	Liver	Kidney	Spleen
Control	4.00 ± 0.38	0.93 ± 0.07	0.22 ± 0.04
DMN	2.33 ± 0.53 [*]	1.22 ± 0.11 [#]	0.51 ± 0.11 [*]
PS (10 mg/kg)	2.99 ± 0.66	1.15 ± 0.15	0.51 ± 0.07
PS (20 mg/kg)	3.53 ± 0.47 [*]	0.99 ± 0.04 [*]	0.40 ± 0.04 [*]

1. DMN was intraperitoneally given at a dose of 10 mg/kg on three days per week for 4 weeks to each group except the control group.

2. The data represent mean ± SD of eight rats.

[#] Significantly different from the control group, $p < 0.05$.

^{*} Significantly different from the group treated with DMN alone, $p < 0.05$.

3.2. Effect of pterostilbene on the biochemical parameters and gross views of livers of the DMN-treated animals

The DMN-alone group exhibited significantly higher serum AST, ALT, and TG levels than those of the control animals, whereas no difference was observed in the serum total cholesterol concentration (Table 2). Pterostilbene supplementation significantly reduced the serum AST and ALT levels induced by DMN; no effect was shown in the serum TG or T-cho levels (Table 2).

3.3. Effect of pterostilbene on the development of fibrosis and the activation of HSC

The morphological changes exhibited DMN-induced hepatic damage, due to significant enhancement of collagen I (Fig. 2) and

Table 2
Effect of pterostilbene (PS) on the serum parameters in the DMN-treated rats.

Groups	Activity			
	GOT (U/L)	GPT (U/L)	TG (mg/dl)	T-cho (mg/dl)
Control	124.00 ± 24.22	49.17 ± 33.00	81.33 ± 15.50	101.83 ± 27.21
DMN	552.67 ± 167.68 [#]	284.33 ± 112.76 [*]	139.83 ± 48.48 [#]	75.00 ± 21.26
PS (10 mg/kg)	300.33 ± 50.25 [*]	180.33 ± 64.99	158.83 ± 82.36	79.67 ± 34.30
PS (20 mg/kg)	174.33 ± 50.25 [*]	103.83 ± 38.06 [*]	143.00 ± 31.76	65.50 ± 8.98

1. DMN was intraperitoneally given at a dose of 10 mg/kg on three days per week for 4 weeks to each group except control group.

2. The data represent the mean ± SD of eight rats.

[#] Significantly different from the control group, $p < 0.05$.

^{*} Significantly different from the group treated with DMN alone, $p < 0.05$.

α -SMA (Fig. 3), as shown in histopathological examinations. In addition, DMN significantly increased the hepatic expression of α -SMA and MMP2 (Fig. 4A), whereas pterostilbene supplementation inhibited their expression, indicating a suppressive effect of pterostilbene on the activation of hepatic stellate cells. Since TGF- β signaling is a major inducer in the development of liver fibrosis, we also examined the expression of several genes in the pathway. As shown in Fig. 4B, DMN treatment increased the expression levels of TGF- β 1, pSmad2, and pSmad3, whereas PS significantly reduced their expression, suggesting that PS supplementation suppressed the DMN-induced TGF- β 1/Smad signaling.

4. Discussion

The biochemical and histopathological changes in the animal models of the DMN-induced liver damage have been well characterised to be comparable to liver injury in humans (George & Chandrakasan, 2000; Ohara, Nii, Sakiyama, Tsuchiya, & Ogawa, 2008). Using an animal model of DMN-induced liver injury, we found that DMN intoxication inhibited animals' appetite and growth, damaged liver function, increased α -SMA and collagen I expression, and initiated hepatic fibrogenesis. However, pterostilbene supplementation alleviated DMN-induced damage as shown by increasing relative weight of liver and spleen, improving biochemical parameters of liver function and histopathological manifestations of hepatic morphology. We and others have demonstrated that pterostilbene exhibits pleiotropic pharmacological effects including anti-inflammatory, antioxidant, anti-proliferatory, anti-cancer, and pain-relieving activities in cell culture and animal studies, to name a few (Chiou et al., 2010; Pan et al., 2009; Remsberg et al., 2008). The finding of the current study added another beneficial effect of pterostilbene on liver injury.

Reactive oxygen species (ROS) have been implicated in many disorders (Caro & Cederbaum, 2004). A status of increased oxidative stress and weakened antioxidant defense associates with various settings of chronic liver disease (CLD), regardless of etiology and fibrosis progression (Parola & Robino, 2001). In essence, ROS plays a critical role in the initiation and progression of CLD (Vitaglione, Morisco, Caporaso, & Fogliano, 2004). In liver, ROS may result from damaged hepatocytes, activated inflammatory cells such as Kupffer cells and neutrophils, and injured mitochondria; these factors may be further modulated by the presence of metals such as iron and copper, ethanol, and pro-oxidant agents, among others (Parola & Robino, 2001). The pro-inflammatory cytokines such as tumour necrosis factor- α (TNF- α) and fibrogenic mediators such as transforming growth factor- β (TGF- β) are responsible for a series of inflammatory and fibrotic process which may ultimately lead to cirrhosis, and evolve into hepatocellular carcinoma (Vitaglione et al., 2004).

Hepatic stellate cells (HSC) play a critical role during fibrosis. Specifically, TGF- β 1/Smad signaling activates HSC, increases collagen expression and deposition, and regulates MMP expression (Yang et al., 2011). Oxidative stress further activates hepatic stellate

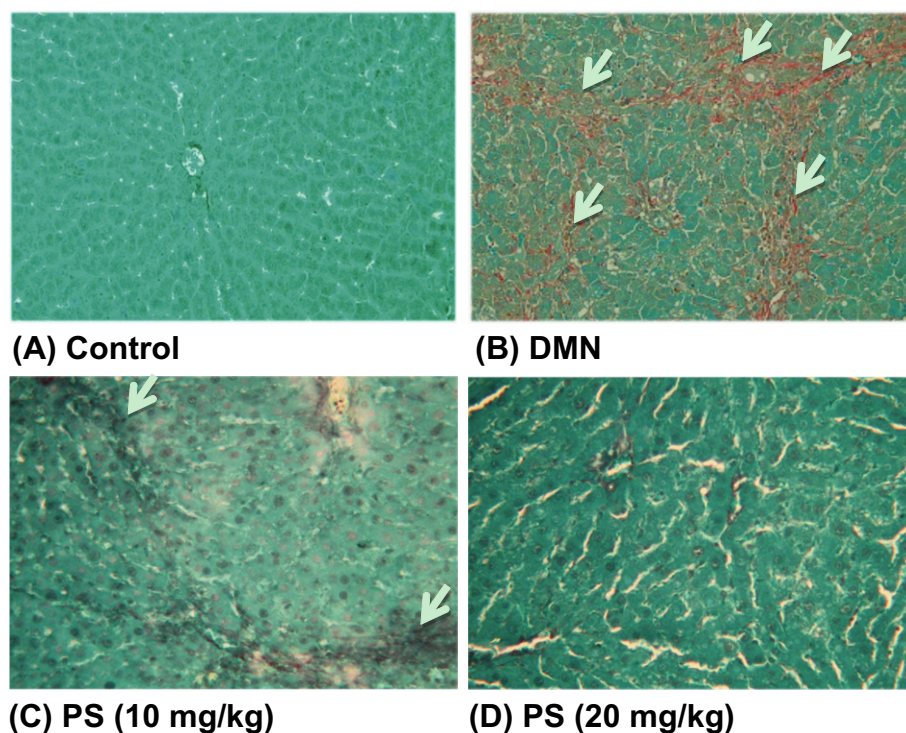


Fig. 2. Pterostilbene attenuates collagen deposition in the dimethyl n-nitrosamine (DMN)-treated animals. Sirius red staining of the liver tissue sections was performed in the control group (A), DMN rats (B), DMN rats receiving 10 mg/kg (C) or 20 mg/kg (D) of pterostilbene.

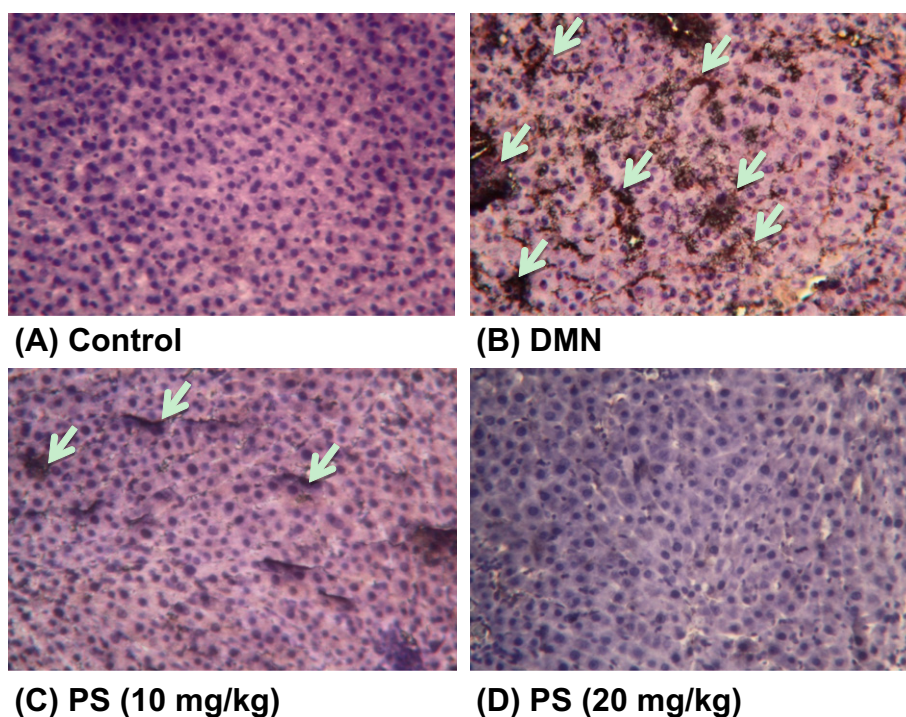


Fig. 3. Pterostilbene attenuates α -smooth muscle actin formation in the dimethylnitrosamine (DMN)-treated animals. Immunohistochemically staining of the liver tissue sections for α -SMA was performed in control rats and dimethylnitrosamine (DMN)-treated animals, with or without the addition of pterostilbene (PS) as indicated.

cells, which not only proliferate but also switch to α -smooth muscle actin (α -SMA)-expressing myofibroblastic phenotypes (Friedman, 2008b; Gressner et al., 2007), produce excessive extracellular matrix (ECM) proteins, including collagen type I (Friedman, 2008a), and secrete tissue inhibitor of matrix metalloproteinase to favour

ECM protein accumulation rather than degradation (Kisseleva & Brenner, 2006). Gradually normal liver tissue is replaced by cross-linking collagen, scar-like matrix tissue (Elsharkawy, Oakley, & Mann, 2005). If no intervention is taken at this stage, the pathological process will further advance into cirrhosis, whereas proper

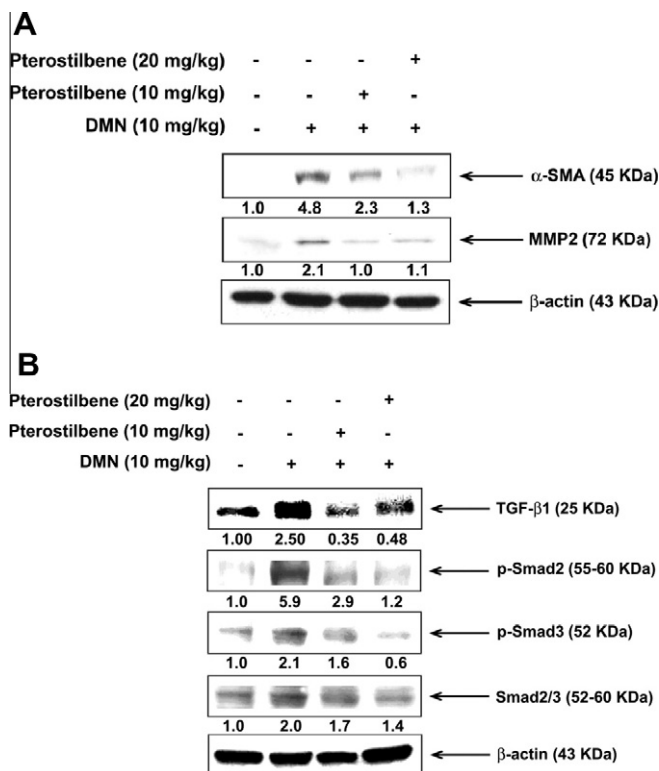


Fig. 4. Effect of pterostilbene (PS) on the expression of α -SMA and MMP2 and the TGF- β signaling in the DMN-treated rats. DMN was given intraperitoneally at a dose of 10 mg/kg body weight on every Monday, Wednesday, and Friday for four consecutive weeks to each group except the control group. DMN (10 mg/kg), DMN alone; PS (10 mg/kg), DMN with 10 mg/kg pterostilbene supplementation by oral gavage daily; PS (20 mg/kg), DMN with 20 mg/kg pterostilbene supplementation by oral gavage daily. Total liver cell lysates were analyzed for the protein expression of α -SMA, MMP2, TGF- β 1, p-Smad2, p-Smad3, and Smad2/3 by Western blotting analysis where β -actin was the loading control.

measures may reverse the fibrosis development. Among matrix metalloproteinase (MMP) family members, MMP2 has been found to be responsible for hepatic fibrogenesis (Strongin et al., 1995). Our current study reported an increase of MMP2 upon DMN-induced liver fibrosis which is reminiscent of a recent report that indicated an increase of the hepatic MMP2 mRNA expression in a CCl₄-induced liver fibrosis model in Sprague–Dawley rats (Kim, Kim, Lee, & Lee, 2011). In addition, we found that the increased MMP2 was suppressed upon pterostilbene treatment, further supporting a protective role of pterostilbene in liver fibrosis.

Some potential anti-fibrotic targets may include induction of HSC apoptosis and elimination of profibrogenic pathways, where inducing apoptosis of activated HSC appears to drive the regression of liver fibrosis (Kisseleva & Brenner, 2006). Inactivation of hepatic stellate cells to prevent liver from further damage becomes a promising anti-fibrotic strategy. The inhibitory effect of pterostilbene on the activation of HSC as evidenced by the reduction of collagen I and α -SMA, suggesting a favourable role of pterostilbene in the treatment of chronic liver disease.

Two studies, relevant to our data, reported that resveratrol inhibited fibrogenesis in DMN-induced liver injury (Hong, Jung, Zheng, Lee, et al., 2010; Lee, Shin, Yoon, & Moon, 2010). One group used a single intraperitoneal injection of DMN (40 mg/kg) to induce liver injury and then administered resveratrol (10 mg/kg) for a week to rescue the damage. The authors found that resveratrol can improve DMN-induced liver injury by increasing antioxidant enzymes and decreasing the expression of collagen I, α -SMA, and TGF- β (Hong et al., 2010). This experimental plan is somewhat

“more acute” than that of ours because of a single, higher (40 mg/kg) dose of DMN and a shorter duration of resveratrol (10 mg/kg for a week) as opposed to 10 mg/kg for 4 weeks.

The other study design (Lee et al., 2010), similar to our experimental layout, also employed an animal model of DMN-induced liver fibrosis. DMN (10 mg/kg) was given by intraperitoneal injection three consecutive days a week and resveratrol (20 mg/kg) was administered by oral gavages daily for 4 weeks. The authors found that resveratrol reduces the DMN-induced oxidative status because of its antioxidant activity. In addition, resveratrol inactivated the HSC activation by reducing the expression of α -SMA and TGF- β .

When comparing the antioxidant activity of resveratrol and pterostilbene, Mikstacka et al. found that pterostilbene was more effective in protecting erythrocyte membrane against lipid peroxidation (Mikstacka, Rimando, & Ignatowicz, 2010). In the current study, we did not measure the hepatic level of malondialdehyde, a product of lipid oxidation; however, pterostilbene may have a similar effect, if not greater, as that of resveratrol on the reduction of the oxidative status. In addition, pterostilbene has only one hydroxyl group while resveratrol has three, which presumably increase transport into cells and metabolic stability of pterostilbene (Baur & Sinclair, 2006). Furthermore, pterostilbene exhibited a better pharmacokinetic profile than that of resveratrol, which ultimately makes pterostilbene as a better drug candidate than resveratrol (Baur & Sinclair, 2006; Lin, Yue, & Ho, 2009). Therefore, pterostilbene is predicted better than, or at least comparable to, resveratrol in biological application.

Pterostilbene's strong antioxidant and anti-inflammatory properties contribute to its diverse pharmacological effects, which may include inhibition of HSC activation and secretion of profibrogenic cytokines during the development of liver fibrogenesis. Our data demonstrated that pterostilbene exhibited hepatoprotective effects in DMN-induced experimental fibrosis and implicated its potential application in clinical intervention.

Acknowledgements

This work was supported by the grants of the National Science Council, Taiwan, ROC (NSC 98-2320-B-309-002-MY3 to M.-F. Lee and 100-2321-B-022-001 to M.-H. Pan).

References

- Adrian, M., Jeandet, P., Douillet-Breuil, A. C., Tesson, L., & Bessis, R. (2000). Stilbene content of mature *Vitis vinifera* berries in response to UV-C elicitation. *Journal of Agricultural and Food Chemistry*, 48(12), 6103–6105.
- Ala-Kokko, L., Pihlajaniemi, T., Myers, J. C., Kivirikko, K. I., & Savolainen, E. R. (1987). Gene expression of type I, III and IV collagens in hepatic fibrosis induced by dimethylnitrosamine in the rat. *Biochemical Journal*, 244(1), 75–79.
- Bataller, R., & Brenner, D. A. (2005). Liver fibrosis. *The Journal of Clinical Investigation*, 115(2), 209–218.
- Baur, J. A., & Sinclair, D. A. (2006). Therapeutic potential of resveratrol: The in vivo evidence. *Nature Reviews Drug Discovery*, 5(6), 493–506.
- Caldwell, S., & Park, S. H. (2009). The epidemiology of hepatocellular cancer: From the perspectives of public health problem to tumor biology. *Journal of Gastroenterology*, 44(Suppl. 19), 96–101.
- Caro, A. A., & Cederbaum, A. I. (2004). Oxidative stress, toxicology, and pharmacology of CYP2E1. *Annual Review of Pharmacology and Toxicology*, 44, 27–42.
- Chiou, Y. S., Tsai, M. L., Wang, Y. J., Cheng, A. C., Lai, W. M., Badmaev, V., et al. (2010). Pterostilbene inhibits colorectal aberrant crypt foci (ACF) and colon carcinogenesis via suppression of multiple signal transduction pathways in azoxymethane-treated mice. *Journal of Agricultural and Food Chemistry*, 58(15), 8833–8841.
- Douillet-Breuil, A. C., Jeandet, P., Adrian, M., & Bessis, R. (1999). Changes in the phytoalexin content of various *Vitis* spp. in response to ultraviolet C elicitation. *Journal of Agricultural and Food Chemistry*, 47(10), 4456–4461.
- Elsharkawy, A. M., Oakley, F., & Mann, D. A. (2005). The role and regulation of hepatic stellate cell apoptosis in reversal of liver fibrosis. *Apoptosis*, 10(5), 927–939.
- Friedman, S. L. (2003). Liver fibrosis – From bench to bedside. *Journal of Hepatology*, 38(Suppl. 1), S38–S53.
- Friedman, S. L. (2008a). Hepatic fibrosis – Overview. *Toxicology*, 254(3), 120–129.

- Friedman, S. L. (2008b). Hepatic stellate cells: Protean, multifunctional, and enigmatic cells of the liver. *Physiological Reviews*, 88(1), 125–172.
- George, J., & Chandrakasan, G. (1996). Glycoprotein metabolism in dimethylnitrosamine induced hepatic fibrosis in rats. *International Journal of Biochemistry and Cell Biology*, 28(3), 353–361.
- George, J., & Chandrakasan, G. (2000). Biochemical abnormalities during the progression of hepatic fibrosis induced by dimethylnitrosamine. *Clinical Biochemistry*, 33(7), 563–570.
- George, J., Rao, K. R., Stern, R., & Chandrakasan, G. (2001). Dimethylnitrosamine-induced liver injury in rats: The early deposition of collagen. *Toxicology*, 156(2–3), 129–138.
- Gressner, O. A., Weiskirchen, R., & Gressner, A. M. (2007). Biomarkers of hepatic fibrosis, fibrogenesis and genetic pre-disposition pending between fiction and reality. *Journal of Cellular and Molecular Medicine*, 11(5), 1031–1051.
- Hong, S. W., Jung, K. H., Zheng, H. M., Lee, H. S., et al. (2010). The protective effect of resveratrol on dimethylnitrosamine-induced liver fibrosis in rats. *Archives of Pharmacological Research*, 33(4), 601–609.
- Kim, H. Y., Kim, S. J., Kim, K. N., Lee, S. G., & Lee, S. M. (2011). Protective effect of HV-P411, an herbal mixture, on carbon tetrachloride-induced liver fibrosis. *Food Chemistry*, 124, 248–253.
- Kisseleva, T., & Brenner, D. A. (2006). Hepatic stellate cells and the reversal of fibrosis. *Journal of Gastroenterology and Hepatology*, 21(Suppl. 3), S84–S87.
- Lee, E. S., Shin, M. O., Yoon, S., & Moon, J. O. (2010). Resveratrol inhibits dimethylnitrosamine-induced hepatic fibrosis in rats. *Archives of Pharmacological Research*, 33(6), 925–932.
- Lin, H. S., Yue, B. D., & Ho, P. C. (2009). Determination of pterostilbene in rat plasma by a simple HPLC-UV method and its application in pre-clinical pharmacokinetic study. *Biomedical Chromatography*, 23(12), 1308–1315.
- Mann, C. D., Neal, C. P., Garcea, G., Manson, M. M., Dennison, A. R., & Berry, D. P. (2009). Phytochemicals as potential chemopreventive and chemotherapeutic agents in hepatocarcinogenesis. *European Journal of Cancer Prevention*, 18(1), 13–25.
- Mikstacka, R., Rimando, A. M., & Ignatowicz, E. (2010). Antioxidant effect of trans-resveratrol, pterostilbene, quercetin and their combinations in human erythrocytes in vitro. *Plant Foods for Human Nutrition*, 65(1), 57–63.
- Moreira, R. K. (2007). Hepatic stellate cells and liver fibrosis. *Archives of Pathology and Laboratory Medicine*, 131(11), 1728–1734.
- Ohara, F., Nii, A., Sakiyama, Y., Tsuchiya, M., & Ogawa, S. (2008). Pathophysiological characteristics of dimethylnitrosamine-induced liver fibrosis in acute and chronic injury models: A possible contribution of KLF5 to fibrogenic responses. *Digestive Diseases and Sciences*, 53(8), 2222–2232.
- Pan, M. H., Chiou, Y. S., Chen, W. J., Wang, J. M., Badmaev, V., & Ho, C. T. (2009). Pterostilbene inhibited tumor invasion via suppressing multiple signal transduction pathways in human hepatocellular carcinoma cells. *Carcinogenesis*, 30(7), 1234–1242.
- Parola, M., & Robino, G. (2001). Oxidative stress-related molecules and liver fibrosis. *Journal of Hepatology*, 35(2), 297–306.
- Remsberg, C. M., Yanez, J. A., Ohgami, Y., Vega-Villa, K. R., Rimando, A. M., et al. (2008). Pharmacometrics of pterostilbene: Preclinical pharmacokinetics and metabolism, anticancer, antiinflammatory, antioxidant and analgesic activity. *Phytotherapy Research*, 22(2), 169–179.
- Rossi, E., Adams, L. A., Bulsara, M., & Jeffrey, G. P. (2007). Assessing liver fibrosis with serum marker models. *The Clinical Biochemist Reviews*, 28(1), 3–10.
- Strongin, A. Y., Collier, I., Bannikov, G., Marmer, B. L., Grant, G. A., & Goldberg, G. I. (1995). Mechanism of cell surface activation of 72-kDa type IV collagenase. Isolation of the activated form of the membrane metalloprotease. *The Journal of Biological Chemistry*, 270(10), 5331–5338.
- Szajdek, A., & Borowska, E. J. (2008). Bioactive compounds and health-promoting properties of berry fruits: A review. *Plant Foods for Human Nutrition*, 63(4), 147–156.
- Vitaglione, P., Morisco, F., Caporaso, N., & Fogliano, V. (2004). Dietary antioxidant compounds and liver health. *Critical Reviews in Food Science and Nutrition*, 44(7–8), 575–586.
- Yang, C. S., Tu, Y. Y., Koop, D. R., & Coon, M. J. (1985). Metabolism of nitrosamines by purified rabbit liver cytochrome P-450 isozymes. *Cancer Research*, 45(3), 1140–1145.
- Yang, J., Zheng, J., Wu, L., Shi, M., Zhang, H., Wang, X., et al. (2011). NDRG2 ameliorates hepatic fibrosis by inhibiting the TGF-beta1/Smad pathway and altering the MMP2/TIMP2 ratio in rats. *PLoS One*, 6(11), e27710.
- Yoo, J. S., Guengerich, F. P., & Yang, C. S. (1988). Metabolism of N-nitrosodialkylamines by human liver microsomes. *Cancer Research*, 48(6), 1499–1504.
- Zhou, K., & Lu, L. G. (2009). Assessment of fibrosis in chronic liver diseases. *Journal of Digestive Diseases*, 10(1), 7–14.