



Expression of hyaluronic acid in *N*-nitrosodimethylamine induced hepatic fibrosis in rats

Joseph George, Mikihiro Tsutsumi*, Shujiro Takase¹

Division of Gastroenterology, Department of Internal Medicine, Kanazawa Medical University, Uchinada, Ishikawa 920-0293, Japan

Received 12 March 2003; received in revised form 5 June 2003; accepted 16 June 2003

Abstract

Hyaluronic acid (HA) plays prominent role in the pathogenesis of liver fibrosis. The mechanism of increased serum and liver HA during hepatic fibrosis was studied in rats. Liver injury was induced by intraperitoneal injections of *N*-nitrosodimethylamine (NDMA) for 7 consecutive days. A group of animals were sacrificed on everyday during injection and also on days 14 and 21 after the start of NDMA administration. The α -smooth muscle actin (α -SMA) was stained as a marker for activated stellate cells. Liver HA was studied by histochemical methods and serum HA was monitored by HA binding protein assay. CD44 was stained immunohistochemically. After the start of NDMA administration, necrosis was initiated on day 3 and massive necrosis was observed on days 5 and 7. Fibrosis was developed on day 14 and early cirrhosis was present on day 21. Staining of α -SMA demonstrated activated stellate cells from day 3 onwards. Serum HA peaked on day 7 and reduced afterwards. Serial liver sections stained for HA revealed excessive accumulation of HA during NDMA administration. On days 14 and 21, α -SMA and HA staining was remarkable in fibrotic and cirrhotic areas. CD44 staining was negative except during necrosis. It is concluded that the early elevation of serum HA is due to the increased synthesis and simultaneous release from the necrotic liver. In latter stages the increase of both serum and liver HA is contributed by the increased synthesis by the activated stellate cells and reduced clearance by the impaired sinusoidal endothelial cells.

© 2003 Elsevier Ltd. All rights reserved.

Keywords: Hyaluronic acid; CD44; *N*-nitrosodimethylamine; Stellate cells; Hepatic fibrosis; Liver cirrhosis

1. Introduction

Hyaluronic acid (HA) is an important component of extracellular matrix and present in all tissues and organs of the body. One of the primary roles of HA is to retain water and regulate water flow in the extracellular matrix, which is important for structural organization of the tissue (Heinegard & Paulsson, 1984). HA

also plays vital roles in cell migration, recognition, adhesion and cell behavior including differentiation, proliferation and tissue morphogenesis (Lee & Spicer, 2000; Toole, 2001). In the liver, HA is mainly synthesized by the stellate cells present in the sinusoidal areas (Gressner & Haarmann, 1988a,b; Vrochides, Papanikolaou, Pertoft, Antoniadis, & Heldin, 1996). Sinusoidal endothelial cells are the prominent sites of HA degradation (Eriksson, Fraser, Laurent, Pertoft, & Smedsrod, 1983; Fraser, Alcorn, Laurent, Robinson, & Ryan, 1985; Saegusa, Isaji, & Kawarada, 2002). It has been reported that the capillarisation of sinusoids accompanied by the appearance of basement membrane in the space of Disse and decrease in the

* Corresponding author. Tel.: +81-76-286-2211x2810; fax: +81-76-286-2412.

E-mail addresses: tsutsumi@kanazawa-med.ac.jp (M. Tsutsumi), s-takase@kanazawa-med.ac.jp (S. Takase).

¹ Tel.: +81-76-286-2211x3511; fax: +81-76-286-0892.

number of fenestrae of the endothelial cells during hepatic fibrosis is contributed by the accumulation of HA (Kobayashi, Horikoshi, Yamataka, Yamataka, Okazaki, Lane, & Miyano, 1999). It was reported that serum HA elevates drastically during liver fibrosis and suggested as a marker for alcoholic liver diseases (Grzeszczuk, Chlabicz, & Panasiuk, 2002; Korner, Kropf, & Gressner, 1996; Plevris et al., 2000; Stickel et al., 2001; Tsutsumi et al., 1997). But the mechanism of increase in serum HA during hepatic fibrosis and alcoholic cirrhosis is not very clear.

CD44 is an adhesion molecule, which binds hyaluronic acid and participates in a number of cell–cell and cell–matrix interactions (Yasuda, Nakano, Yasumoto, & Tanaka, 2002). Hyaluronic acid metabolism is mainly regulated by the cell surface receptor, CD44 (Lesley & Hyman, 1998; Naot, Sionov, & Ish-Shalom, 1997). In the liver, CD44 is expressed on sinusoidal endothelial cells (Satoh, Ichida, Matsuda, Sugiyama, Yonekura, Ishikawa, Asakura, 2000; Scoazec, 1995). Increased expression of CD44 has been reported in alcoholic liver disease (Urashima, Tsutsumi, Ozaki, Tsuchishima, Shimanaka, Ueshima, Takase, 2000) and dimethylnitrosamine induced liver cirrhosis (Satoh et al., 2000). Since CD44 is the major receptor for HA and also involves in HA degradation (Tamaki, Ueno, Torimura, Sata & Tanikawa, 1996), modulation of CD44 expression in various pathological conditions including hepatic fibrosis could alter HA metabolism or its accumulation in body fluids and tissues.

It has been demonstrated that *N*-nitrosodimethylamine (NDMA) induced liver injury in rats is a good and reproducible animal model for studying biochemical and pathophysiological alterations associated with the development of hepatic fibrosis and cirrhosis (Jenkins et al., 1985; Jezequel et al., 1987; George & Chandrakasan, 1996a; George & Chandrakasan, 1996b). Since fibrosis and cirrhosis results increased accumulation of connective tissue components in the liver, studies on the expression of extracellular matrix proteins are of considerable relevance. The aim of the present study was to understand the probable mechanism of increased serum and liver HA during hepatic fibrosis. In order to comprehend this, we have monitored the expression of HA in the liver and HA levels in the serum on consecutive days during the progression of NDMA induced hepatic fibrosis and

cirrhosis in rats. Since modulation of CD44 expression could alter HA metabolism, we have examined the expression of CD44 also in serial liver sections during the progression of hepatic fibrosis.

2. Materials and methods

2.1. Chemicals

N-nitrosodimethylamine was purchased from Sigma Chemical Company, USA. Immunohistochemical kit (LSAB2) was procured from DAKO Corporation, Carpinteria, USA. The CD44 and α -smooth muscle actin (α -SMA) antibodies were obtained from Nichirei Corporation, Tokyo, Japan. Hyaluronic acid binding protein was procured from Chugai Pharmaceuticals, Tokyo, Japan.

2.2. Induction of hepatic fibrosis

Twelve weeks old male albino rats of the Wistar strain, weighing around 200 g were used for the experiment. The animals were maintained with commercial rat feed (Nihon Nousan Industry, Yokohama, Japan) and water available ad libitum. They were housed in polypropylene cages with a wire mesh top and a hygienic bed of soft wood scrapings with proper humane care. Hepatic fibrosis was induced by intraperitoneal injections of *N*-nitrosodimethylamine in doses of 1 mg (prepared in 0.15 M sterile NaCl)/100 g body weight for 7 consecutive days. Control animals also received similar injections of 0.15 M NaCl without NDMA. The injections were given without anesthesia. A group of animals were sacrificed on every day during injection and also on days 14 and 21 from the beginning of the exposure. Some of the control animals were sacrificed at the beginning of the experiment and some together with the treated animals on days 7, 14 and 21 and the pooled value was used as control. The control and the experimental group up to day 7 comprised six rats each, while the day 14 and 21 group consisted four rats each. All animals were anesthetized with diethyl ether before sacrifice. Blood was collected from the orbital sinus of the animal by piercing a heparinised capillary tube during anesthesia (Tsutsumi et al., 1990). About 2–3 ml blood was collected by this method. Blood was also collected

from a deep cut made on the right jugular vein on the neck. The liver tissue was quickly removed and a portion was instantly fixed in 10% phosphate buffered formalin. The body weight and liver weight of the animals were monitored throughout the study.

2.3. Evaluation of hepatic fibrosis

The progression of hepatic fibrosis was evaluated by hematoxylin and eosin and Masson's trichrome staining. Serial sections were stained and examined under an Olympus photomicroscope (Olympus corporation, Tokyo, Japan) and photographed. The activation of liver stellate cells indicated by the staining of α -smooth muscle actin filaments is also considered as a marker for the degree of hepatic fibrosis induced by NDMA.

2.4. Biochemical analyses

The alanine transaminase (ALT) and aspartate transaminase (AST) levels in the serum were assayed as a measure of hepatic injury. Both ALT and AST levels were determined using an auto-analyser. Serum hyaluronan (HA) concentrations were determined using an ELISA-based sandwich HA binding protein assay kit (Chugai Diagnostics Science, Tokyo, Japan), which follows the method of Chichibu et al. (Chichibu, Matsuura, Shichijo, & Yokoyama, 1989).

2.5. Staining of hyaluronic acid, CD44 and α -smooth muscle actin

Serial liver sections were stained histochemically for hyaluronic acid using specific HA binding protein. The same serial sections were used for the staining of α -smooth muscle actin (α -SMA) and CD44 immunohistochemically using α -SMA and CD44 monoclonal antibodies (Nichirei Corporation, Tokyo, Japan) respectively. Paraffin liver sections were deparaffinized using xylene and alcohol and washed in cold phosphate buffered saline (PBS). The endogenous peroxidase activity present in the liver sections was quenched by incubating the specimens with 3% hydrogen peroxide for 10 min. The specimens were then washed in PBS and treated with few drops of biotinylated HA binding protein (2 μ g/ml) and incubated for 1 h in a moisturized chamber at room

temperature. In the case of α -SMA and CD44, monoclonal antibodies raised in mouse were used. The α -SMA antibody was used directly without dilution and the CD44 antibody was diluted 100 times with PBS. The sections were then washed thoroughly in cold PBS, treated with few drops of biotinylated anti-rabbit and anti-mouse immunoglobulins and incubated for 30 min at room temperature. The slides were washed and further treated with horseradish peroxidase labeled streptavidin and incubated. Color was developed using 3% 3-amino-9-ethylcarbazole in *N,N*-dimethylformamide. Stained slides were rinsed in PBS and counter stained with Mayer's hematoxylin. Sections were mounted using aqueous based mounting medium.

2.6. Statistical analysis

Arithmetic mean and standard deviation were calculated for the data. The results were statistically evaluated using one-way analysis of variance (ANOVA). The control mean values were compared with the treated mean values on different days by the least significant difference method. The value of $P < 0.05$ was considered as statistically significant.

3. Results

3.1. Animal body weight and liver weight

The NDMA administered animals did not gain body weight during the course of treatment. A significant decrease was noticed in the mean body weight of the animals on days 14 and 21 after the start of NDMA administration. Similarly, the liver weight was also reduced significantly on days 14 and 21. About 28% decrease was observed in the liver weight on day 14 and 43% decrease on day 21, when compared with the control value.

3.2. Serum AST and ALT

The serum AST and ALT levels after the start of NDMA administration are demonstrated in Fig. 1. The serum AST levels were significantly ($P < 0.001$) increased on days 3–7. The maximum elevation (about 30-fold) was recorded on day 7. The increased AST

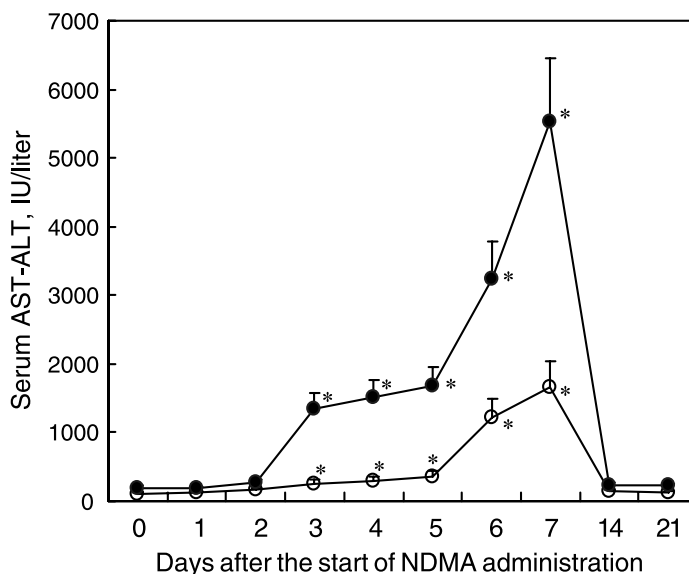


Fig. 1. Aspartate transaminase (●) and alanine transaminase (○) levels in serum during NDMA induced hepatic fibrosis in rats. (* $P < 0.001$ by ANOVA when compared with control).

levels were dramatically reduced to the normal value on day 14 after discontinuing NDMA administration on day 7. The normal level was maintained on day 21 also where cirrhosis was present. Serum ALT levels were also significantly increased on days 3–7 after the start of NDMA administration. The maximum increase was on day 7 (about 16-fold). The increased serum ALT levels were decreased to the normal value on day 14 and maintained on day 21.

3.3. Serum hyaluronic acid

Fig. 2 depicts serum HA levels during NDMA induced hepatic fibrosis. The serum HA was significantly ($P < 0.001$) increased on all days after the start of NDMA administration. The maximum increase observed on day 7, which was about 25-fold higher compared to the control value. After discontinuing NDMA administration on day 7, the serum HA level was considerably decreased on days 14 and 21 but not attained the normal value and the values on both days were still significantly ($P < 0.001$) higher. On day 14, the serum HA level was five-fold higher and on day 21, it was three-fold higher when compared to the control value. This observation is interesting and important since both AST and ALT levels in serum attained

normal value on day 14 after discontinuing NDMA administration on day 7.

3.4. Hematoxylin and eosin staining

The hematoxylin and eosin staining of liver specimens during NDMA administration is demonstrated

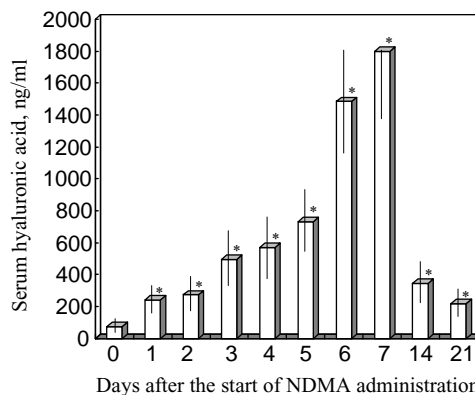


Fig. 2. Hyaluronic acid (HA) levels in serum during NDMA induced hepatic fibrosis in rats. Serum HA concentrations were determined by using sandwich enzyme binding assay kit. (* $P < 0.001$ by ANOVA when compared with control).

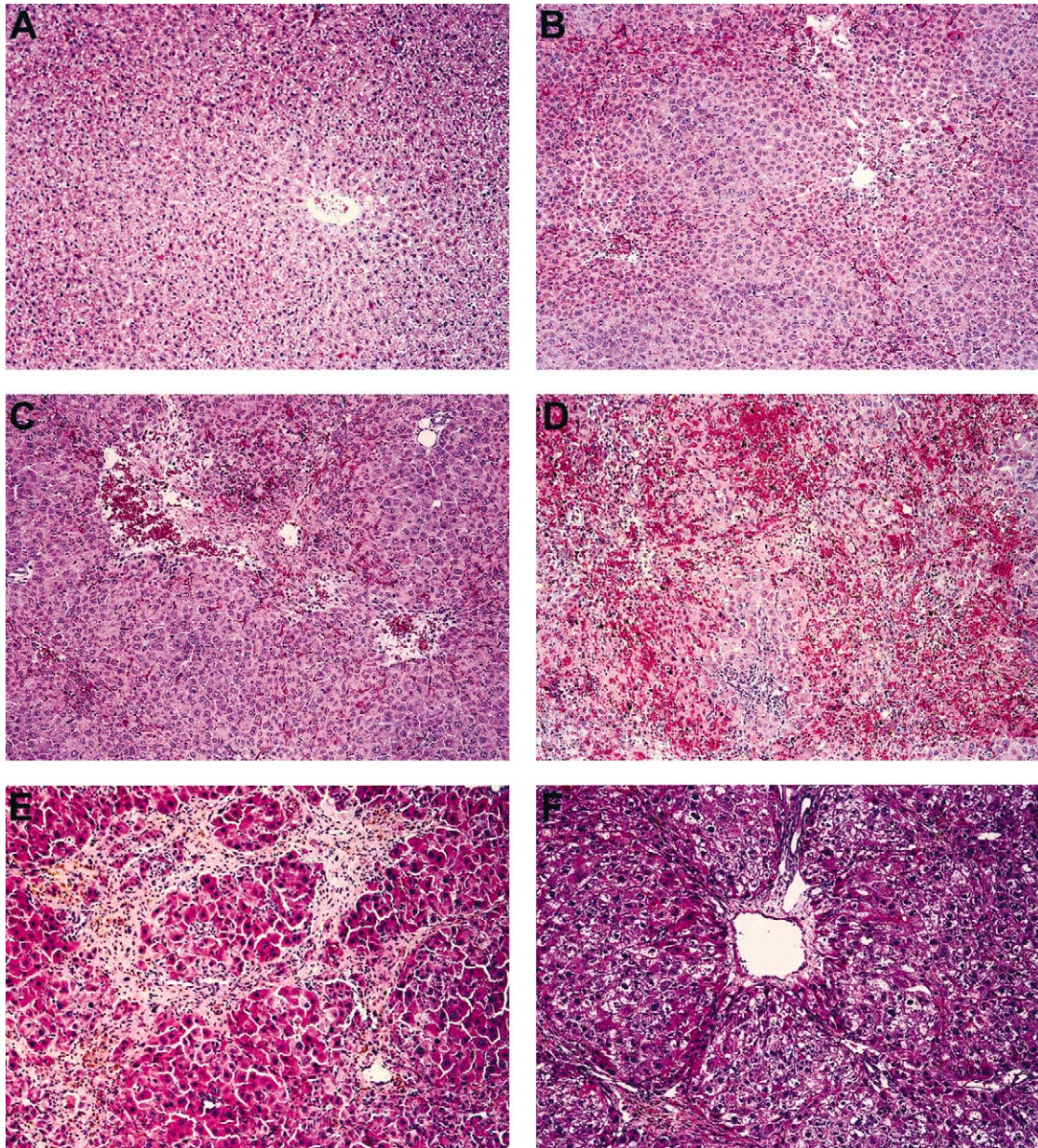


Fig. 3. Hematoxylin and Eosin (H&E) staining of rat liver after NDMA administration demonstrating necrosis. (A) Normal liver ($\times 100$). (B) NDMA 3 days ($\times 100$). Initiation of necrosis. (C) NDMA 5 days ($\times 100$). Severe centrilobular necrosis and neutrophilic infiltration; (D) NDMA 7 days ($\times 100$). Massive hepatic necrosis. (E) NDMA 14 days ($\times 200$). Hepatic fibrosis. (F) NDMA 21 days ($\times 200$). Early cirrhosis.

in Fig. 3A–F. The control livers showed normal lobular architecture with central vein and radiating hepatic cords (Fig. 3A). On day 3 several foci of spotty necrosis was present with marked dilatation of central

veins (Fig. 3B). On day 5, the liver specimens depicted extensive necrosis and hemorrhage (Fig. 3C). There was marked neutrophilic and mononuclear cell infiltration with severe centrilobular congestion

(Fig. 3C). Massive hepatic necrosis and collapse of the liver parenchyma were observed on day 7 (Fig. 3D). Fibrosis was prominent on day 14 (Fig. 3E). Bridging necrosis was present in certain cases. On

day 21, NDMA treated liver specimens demonstrated intensive fibrosis with thick collagen fibers (Fig. 3F). Lobular disarray and early cirrhosis was also visible.

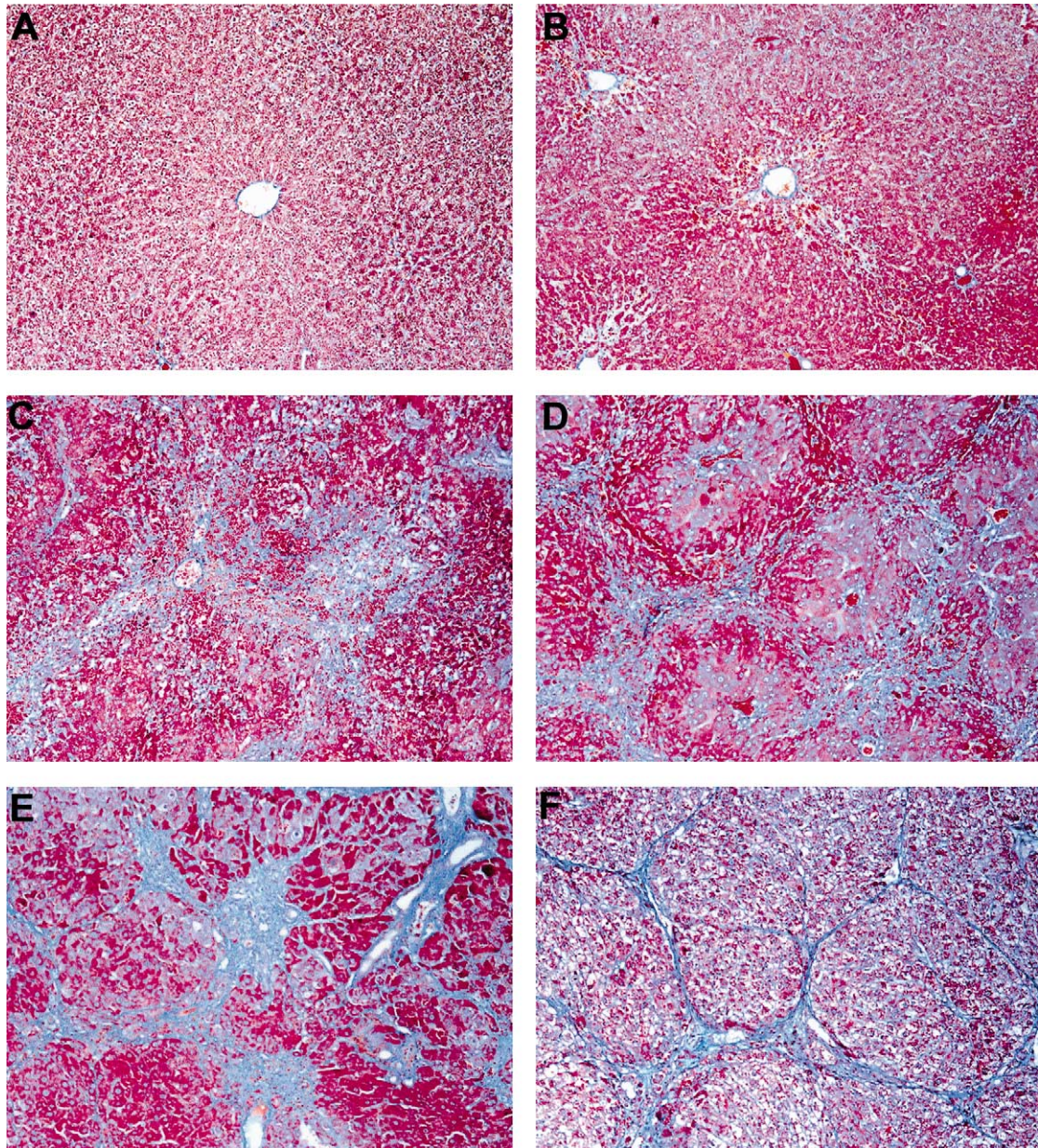


Fig. 4. Masson's trichrome staining of rat liver after NDMA administration demonstrating hepatic fibrosis and cirrhosis. (A) Normal liver ($\times 100$). (B) NDMA 3 days ($\times 100$). Pericentral fibrosis. (C) NDMA 5 days ($\times 100$). Abundant bridging fibrosis. (D) NDMA 7 days ($\times 100$). Fibrosis and initiation of collagen deposition. (E) NDMA 14 days ($\times 100$). Focal fibrosis and early cirrhosis with abundant collagen accumulation. (F) NDMA 21 days ($\times 100$). Cirrhosis with blue collagen fibers.

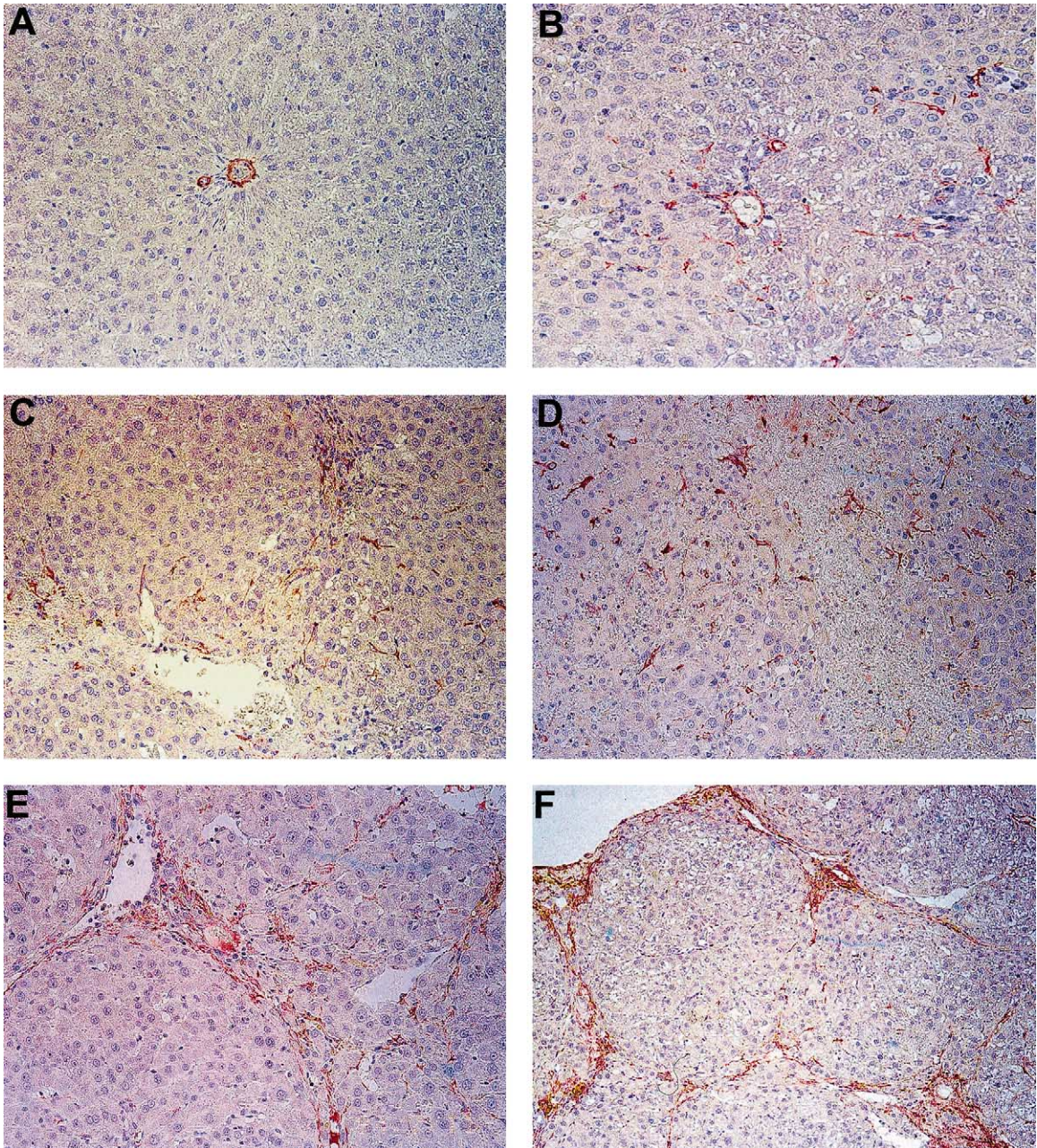


Fig. 5. Immunohistochemical staining of α -smooth muscle actin (α -SMA) demonstrating activated hepatic stellate cells after NDMA administration in rats. (A) Normal liver ($\times 200$). Absence of α -SMA staining. (B) NDMA 3 days ($\times 200$). Positive staining of α -SMA indicating activated stellate cells after NDMA administration. (C) NDMA 5 days ($\times 200$). Abundant staining of activated stellate cells. (D) NDMA 7 days ($\times 200$). Deep staining of α -SMA demonstrating activated stellate cells in the necrotic zone. (E) NDMA 14 days ($\times 200$). α -SMA staining of stellate cells in the fibrotic zone. (F) NDMA 21 days ($\times 100$). Remarkable staining of α -SMA demonstrating enormous number of activated stellate cells in the cirrhotic zone.

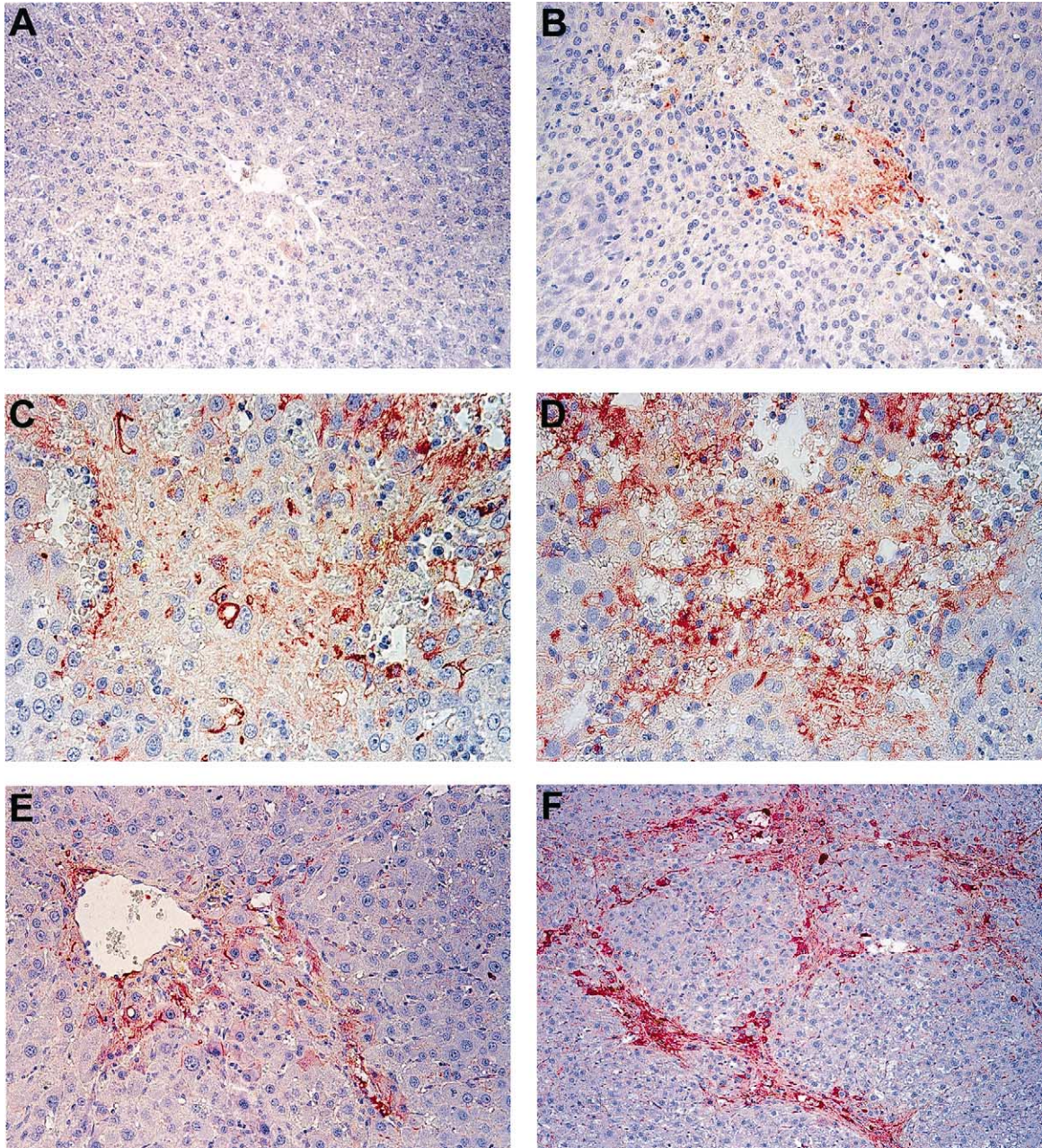


Fig. 6. Histochemical staining of hyaluronic acid in rat liver during NDMA induced hepatic fibrosis and cirrhosis. (A) Normal liver ($\times 200$). Absence of HA staining. (B) NDMA 3 days ($\times 200$). Initiation of HA staining in the necrotic area. (C) NDMA 5 days ($\times 200$). Intensive staining of HA in the necrotic zone. (D) NDMA 7 days ($\times 200$). Fabulous expression of HA in early fibrosis. (E) NDMA 14 days ($\times 200$). Markedly increased staining of HA in the fibrotic zone. (F) NDMA 21 days ($\times 200$). Remarkable expression of HA in the cirrhotic areas.

3.5. Masson's trichrome staining

The Masson's trichrome staining for collagen during NDMA induced hepatic fibrosis is demonstrated in Fig. 4A–F. On day 3, there was slight pericentral fibrosis (Fig. 4B). On day 5, trichrome staining demonstrated abundant bridging fibrosis with initiation of collagen fibers (Fig. 4C). The day 7 liver specimens demonstrated well developed fibrosis (Fig. 4D). There was bluish circular staining pattern around the central vein (Fig. 4D). The lobular architecture was totally distorted. The day 14 liver specimens demonstrated focal fibrosis and early cirrhosis (Fig. 4E). Abundant collagen fibers stained in blue were clearly visible. All liver specimens on day 21 delineated cirrhosis (Fig. 4F). Circumscribed nodules surrounded by well-formed blue collagen fibers were present around central vein.

3.6. Staining of α -smooth muscle actin

The staining of α -SMA for the activated stellate cells is represented in Fig. 5A–F. The α -SMA staining was totally absent in control livers (Fig. 5A). On day 3, a prominent number of stellate cells became activated and stained for α -SMA (Fig. 5B). The number of α -SMA positive stained stellate cells has been further increased on day 5 (Fig. 5C) and day 7 (Fig. 5D). The density of the positive stained stellate cells in the necrotic zone was much higher when compared to the normal areas. On day 14, the staining has been restricted to the fibrotic zone (Fig. 5E). The intensity of the staining was high and the number of positive stained stellate cells in the fibrotic area has also been increased. On day 21, the α -SMA staining was almost confined in the cirrhotic zone (Fig. 5F). The density of the positive stained cells in the cirrhotic area was very high and the intensity of the staining was remarkable.

3.7. Staining of CD44

The CD44 staining was totally absent in control liver sections, on day 3, day 14 (fibrosis) and day 21 (early cirrhosis). However, slight positive staining was present in necrotic areas on day 5 and 7 (data not presented).

3.8. Staining of hyaluronic acid

The histochemical staining of hyaluronic acid using HA binding protein during NDMA administration is depicted in Fig. 6A–F. The HA staining was totally absent in the control liver (Fig. 6A). On day 3, staining was initiated on the necrotic zone (Fig. 6B). On day 5, HA was intensively stained in the necrotic areas (Fig. 6C). On day 7, there was very intensive and remarkable staining of HA in the necrotic and fibrotic zones (Fig. 6D). On day 14, HA staining was almost restricted to the fibrotic areas (Fig. 6E). Specific and remarkable staining of HA was present in the fibrotic and cirrhotic zones on day 21 (Fig. 6F). The HA staining was almost absent in other areas.

4. Discussion

Increased expression, biosynthesis and accumulation of connective tissue proteins are characteristic features of hepatic fibrosis and liver cirrhosis. It has been well established that NDMA induced liver injury in rats is a reproducible and potentially valuable animal model for studying the mechanism of the pathogenesis of hepatic fibrosis and alcoholic cirrhosis (George & Chandrakasan, 2000; George, Rao, Stern & Chandrakasan, 2001; Shiba, Shimizu, Yasuda, Ii, & Ito, 1998). Exposure to repeated lower doses of NDMA causes subacute and chronic liver injury with varying degrees of necrosis, fibrosis and nodular regeneration (Magee & Barnes, 1967).

In the present investigation, Masson's trichrome staining indicated that excessive collagen synthesis initiated on day 5 during NDMA treatment. It is important to note that the activation and transformation of hepatic stellate cells during NDMA treatment initiated as early as on day 3 of NDMA administration (Fig. 5B). It is now well established that activated stellate cells are responsible for excessive collagen synthesis during fibrosis (Brenner et al., 2000; Friedman, 2000; Burt & Oakely, 1993). Masson's staining further depicts that 7 days of serial NDMA administration is sufficient to produce a good fibrotic model. The present scheme of NDMA administration in rats to produce fibrosis and cirrhosis has not been reported earlier. The excellent staining of fibrosis (Fig. 4E) and cirrhosis (Fig. 4F) with blue collagen

bundles demonstrates that the present scheme of NDMA induced hepatic fibrosis and cirrhosis is an excellent animal model for studying the molecular mechanisms involved in the pathogenesis of human hepatic fibrosis and cirrhosis.

The expression of α -smooth muscle actin by the stellate cells is considered as a marker for activated stellate cells (Rockey, Boyles, Gabbiani, & Friedman, 1992). In the present investigation, we have observed that a good percentage of stellate cells were activated on day 3 (Fig. 5B). This indicates the initiation of fibrotic process and beginning of the excessive connective tissue components synthesis as early as on day 3 of NDMA administration. Positive staining for α -SMA was absent on days 1 and 2. On days 14 and 21, the stellate cells are accumulated in the sinusoidal areas in fibrotic and cirrhotic zone. This is indicated by the marked expression of α -SMA by the activated stellate cells in the fibrotic and cirrhotic zone on days 14 and 21. The activated stellate cells thus play a prominent role in the accumulation of collagen and other connective tissue components in the fibrotic areas.

CD44 is a transmembrane glycoprotein involved in the interaction between cells and extracellular matrix. The CD44 present in the sinusoidal endothelial cells is considered as the major receptor for hyaluronic acid in the liver (Aruffo, Stamenkovic, Melnick, Underhill, & Seed, 1990; Sherman, Sleeman, Herrlich, & Ponta, 1994). An increased expression of CD44 has been reported in alcoholic liver diseases (Urashima et al., 2000). A reduction in the amount of CD44 molecule present in sinusoidal endothelial cells was reported in thioacetamide induced liver cirrhosis in rats and suggested as the reason for the marked increase of serum HA in patients with liver cirrhosis (Tamaki et al., 1996). A significant and sustained increase in serum HA levels was also reported after a very low expression of CD44 in thioacetamide induced liver cirrhosis (Saegusa et al., 2002). In the present investigation, CD44 staining was absent in control liver and during the early stages of NDMA administration. However, slight positive staining was present on day 5 (necrosis) and day 7 (early fibrosis). But during advanced fibrosis (day 14) and early cirrhosis (day 21) the CD44 staining was totally absent, which indicates decreased number

of CD44 molecules. Increased staining of liver HA has been reported in alcoholic liver diseases (Urashima, Tsutsumi, Shimanaka, Ueshima, Tsuchishima, Itoh, Kawahara, Takase, 1999). In the present investigation, we have observed a steady state increase in the staining pattern of liver HA after the start of NDMA administration. The staining of HA was initiated in the very beginning of necrosis on day 3. It is important to note that activation of stellate cells also initiated on day 3 after the start of NDMA administration. On days 5 and 7, staining of HA has been increased markedly along with increased number activated stellate cells in the necrotic areas. Furthermore, the staining pattern of HA and activated stellate cells were similar in fibrotic and cirrhotic zones on days 14 and 21, respectively. These suggest that the activated stellate cells would be responsible for the increased synthesis and accumulation of HA in hepatic fibrosis and cirrhosis. It has been reported that HA is mainly synthesized by the hepatic stellate cells present in the sinusoidal areas (Gressner & Haarmann, 1988a,b; Patel et al., 2003; Vrochides et al., 1996). The enhanced synthesis and accumulation of HA along with other connective tissue components in the sinusoidal area play a major role in the formation of basement membrane in the space of Disse and capillarization of sinusoids. The capillarization of sinusoids will lead to the defenestration and impaired function of sinusoidal endothelial cells, which further contribute to the decreased number of CD44 and reduced clearance of serum HA.

Increased serum HA has been suggested as a sensitive marker and a diagnostic tool for hepatic fibrosis (Hasegawa et al., 2000; Nyberg, Engstrom-Laurent, & Loof, 1988; Plevris et al., 2000). In the present study, maximum increase of serum HA was noticed on day 7 (25-fold) when massive hepatic necrosis was present. Even though serum HA concentration has been decreased considerably on days 14 and 21, after discontinuing NDMA administration on day 7, the serum HA levels on both days were significantly ($P < 0.001$) higher when compared to the control value. There was a five-fold increase of serum HA on day 14 and three-fold increase on day 21. This increase of serum HA on day 14 and 21 could be explained by the increased synthesis of HA by the activated stellate cells and simultaneous spillage in to the blood stream. The 25-fold increase of serum HA noticed on day 7 after the start of NDMA

administration was due to the increased synthesis by the activated hepatic stellate cells and simultaneous spillage along with AST and ALT during massive hepatic necrosis. It is important to note that serum AST and ALT levels attained normal value on day 14, while serum HA levels were still five-fold higher. The expression of liver HA was much higher on day 21 than day 14 as evidenced by the marked increase of the histochemical staining of HA on day 21. However, hepatic necrosis was almost absent on day 21 and the same could be explained the decrease of serum HA on day 21 when compared to day 14. Since necrosis was almost absent on day 21, the spillage of the liver HA to the circulation was also reduced.

As discussed earlier, the significant factor for the dramatic elevation of serum HA during NDMA induced hepatic fibrosis is due to the enhanced synthesis of HA and simultaneous release into the blood stream from the necrotic liver. The reduced clearance of HA by the impaired sinusoidal endothelial cells could also be responsible for the increased serum HA. It was reported that the elevated plasma levels of hyaluronic acid indicate endothelial cell dysfunction in the initial stages of alcoholic liver disease in the rat (Nanji, Tahan, Khwaja, Yacoub, & Sadzadeh, 1996). It was also reported that during fibrogenesis in chronically inflamed liver, the concentration of extracellular matrix HA increases several-fold (Gressner & Haarmann, 1988a,b). We also observed a markedly increased staining of HA in the fibrotic and cirrhotic zone after NDMA administration. Since hepatic stellate cells are responsible for the synthesis of HA in liver (Gressner & Haarmann, 1988a,b; Patel et al., 2003; Vrochides et al., 1996), the stellate cell activation and proliferation during fibrogenesis would have triggered an increased expression of HA along with other connective tissue components. Most of the newly synthesized hyaluronate is excreted into the extracellular space, of which a fraction can leak into the blood stream and the process will be accelerated during liver necrosis. It was reported that more than 90% of the circulating HA is degraded in the hepatic sinusoidal endothelial cells (Eriksson et al., 1983; Fraser et al., 1985). During fibrosis the function of the sinusoidal endothelial cells are impaired due to the capillarization of sinusoids and formation of basement membrane in the Space of Disse. Ueno et al. (Ueno et al., 1993) reported that serum hyaluronate reflects the morpholog-

ical and functional changes in the sinusoidal endothelial cells that accompany hepatic sinusoidal capillarization in various liver disorders.

In conclusion, the most significant factor in the dramatic elevation of serum HA in early NDMA induced fibrosis is the increased synthesis of HA by the stellate cells and simultaneous release from the necrotic liver. In advanced fibrosis and cirrhosis the increased serum and liver HA is contributed by the increased synthesis by the activated stellate cells. The reduced clearance of HA by the impaired sinusoidal endothelial cells may also be responsible for the elevation of serum and liver HA during hepatic fibrosis and cirrhosis.

References

- Aruffo, A., Stamenkovic, I., Melnick, M., Underhill, C. B., & Seed, B. (1990). CD44 is the principal cell surface receptor for hyaluronate. *Cell*, *61*, 1303–1313.
- Brenner, D. A., Waterboer, T., Choi, S. K., Lindquist, J. N., Stefanovic, B., Burchardt, E., Yamauchi, M., Gillan, A., & Rippe, R. A. (2000). New aspects of hepatic fibrosis. *Journal of Hepatology*, *32*(Suppl 1), 32–38.
- Burt, A. D., & Oakely, C. L. (1993). Lecture (1993): Cellular and molecular aspects of hepatic fibrosis. *Journal of Pathology*, *170*, 105–114.
- Chichibu, K., Matsuura, T., Shichijo, S., & Yokoyama, M. M. (1989). Assay of serum hyaluronic acid in clinical application. *Clinica Chimica Acta*, *181*, 317–323.
- Eriksson, S., Fraser, J. R. E., Laurent, T. C., Pertoft, H., & Smedsrod, B. (1983). Endothelial cells are a site of uptake and degradation of hyaluronic acid in the liver. *Experimental Cell Research*, *144*, 223–228.
- Fraser, J. R., Alcorn, D., Laurent, T. C., Robinson, A. D., & Ryan, G. B. (1985). Uptake of circulating hyaluronic acid by the rat liver. Cellular localization in situ. *Cell Tissue Research*, *242*, 505–510.
- Friedman, S. L. (2000). Molecular regulation of hepatic fibrosis, an integrated cellular response to tissue injury. *Journal of Biological Chemistry*, *275*, 2247–2250.
- George, J., & Chandrakasan, G. (1996a). Glycoprotein metabolism in dimethylnitrosamine induced hepatic fibrosis in rats. *International Journal of Biochemical Cell Biology*, *28*, 353–361.
- George, J., & Chandrakasan, G. (1996b). Molecular characteristics of dimethylnitrosamine induced fibrotic liver collagen. *Biochimica Biophysica Acta*, *1292*, 215–222.
- George, J., & Chandrakasan, G. (2000). Biochemical abnormalities during the progression of hepatic fibrosis induced by dimethylnitrosamine. *Clinical Biochemistry*, *33*, 563–570.
- Gressner, A. M., & Haarmann, R. (1988a). Regulation of hyaluronate synthesis in rat liver fat storing cell cultures by Kupffer cells. *Journal of Hepatology*, *7*, 310–318.

- Gressner, A. M., & Haarmann, R. (1988b). Hyaluronic acid synthesis and secretion by rat liver fat storing cells (perisinusoidal lipocytes) in culture. *Biochemical and Biophysical Research Communication*, *151*, 222–229.
- George, J., Rao, K. R., Stern, R., & Chandrakasan, G. (2001). Dimethylnitrosamine-induced liver injury in rats: The early deposition of collagen. *Toxicology*, *156*, 129–138.
- Grzeszczuk, A., Chlabicz, S., & Panasiuk, A. (2002). Serum hyaluronan as a possible biomarker of liver insufficiency in cirrhotic patients. *Roczniki Akademii Medycznej w Białymstoku*, *47*, 80–85.
- Hasegawa, T., Sasaki, T., Kimura, T., Hoki, M., Okada, A., Mushiaki, S., Yagi, M., & Imura, K. (2000). Measurement of serum hyaluronic acid as a sensitive marker of liver fibrosis in biliary atresia. *Journal of Pediatric Surgery*, *35*, 1643–1646.
- Heinegard, D., Paulsson, M. (1984). Structure and metabolism of proteoglycans. In K. A. Piez, A. H. Reddi (Eds.), *Extracellular matrix biochemistry* (pp. 277–328). New York: Elsevier.
- Jenkins, S. A., Grandison, A., Baxter, J. N., Day, D. W., Taylor, I., & Shields, R. (1985). A dimethylnitrosamine-induced model of cirrhosis and portal hypertension in the rat. *Journal of Hepatology*, *1*, 489–499.
- Jezequel, A. M., Mancini, R., Rinaldesi, M. L., Macarri, G., Venturini, C., & Orlandi, F. (1987). A morphological study of the early stages of hepatic fibrosis induced by low doses of dimethylnitrosamine in the rat. *Journal of Hepatology*, *5*, 174–181.
- Kobayashi, H., Horikoshi, K., Yamataka, A., Yamataka, T., Okazaki, T., Lane, G. J., & Miyano, T. (1999). Hyaluronic acid: A specific prognostic indicator of hepatic damage in biliary atresia. *Journal of Pediatric Surgery*, *34*, 1791–1794.
- Korner, T., Kropf, J., & Gressner, A. M. (1996). Serum laminin and hyaluronan in liver cirrhosis: Markers of progression with high prognostic value. *Journal of Hepatology*, *25*, 684–688.
- Lee, J. Y., & Spicer, A. P. (2000). Hyaluronan: A multifunctional, megaDalton, stealth molecule. *Current Opinion Cell Biology*, *12*, 581–586.
- Lesley, J., & Hyman, R. (1998). CD44 structure and function. *Front Bioscience*, *3*, D616–D630.
- Magee, P. N., & Barnes, J. (1967). Carcinogenic compounds. *Advanced Cancer Research*, *10*, 163–246.
- Nanji, A. A., Tahan, S. R., Khwaja, S., Yacoub, L. K., & Sadrzadeh, S. M. (1996). Elevated plasma levels of hyaluronic acid indicate endothelial cell dysfunction in the initial stages of alcoholic liver disease in the rat. *Journal of Hepatology*, *24*, 368–374.
- Naot, D., Sionov, R. V., & Ish-Shalom, D. (1997). CD44: Structure, function, and association with the malignant process. *Advanced Cancer Research*, *71*, 241–319.
- Nyberg, A., Engstrom-Laurent, A., & Loof, L. (1988). Serum hyaluronate in primary biliary cirrhosis—a biochemical marker for progressive liver damage. *Hepatology*, *8*, 142–146.
- Patel, K., Lajoie, A., Heaton, S., Pianko, S., Behling, C. A., Bylund, D., Pockros, P. J., Blatt, L. M., Conrad, A., & McHutchison, J. G. (2003). Clinical use of hyaluronic acid as a predictor of fibrosis change in hepatitis C. *Journal of Gastroenterology Hepatology*, *18*, 253–257.
- Plevris, J. N., Haydon, G. H., Simpson, K. J., Dawkes, R., Ludlum, C. A., Harrison, D. J., & Hayes, P. C. (2000). Serum hyaluronan—a non-invasive test for diagnosing liver cirrhosis. *European Journal of Gastroenterology Hepatology*, *12*, 1121–1127.
- Rockey, D. C., Boyles, J. K., Gabbiani, G., & Friedman, S. L. (1992). Rat hepatic lipocytes express smooth muscle actin upon activation in vivo and in culture. *Journal of Submicroscopic Cytology Pathology*, *24*, 193–203.
- Saegusa, S., Isaji, S., & Kawarada, Y. (2002). Changes in serum hyaluronic acid levels and expression of CD44 and CD44 mRNA in hepatic sinusoidal endothelial cells after major hepatectomy in cirrhotic rats. *World Journal of Surgery*, *26*, 694–699.
- Satoh, T., Ichida, T., Matsuda, Y., Sugiyama, M., Yonekura, K., Ishikawa, T., & Asakura, H. (2000). Interaction between hyaluronan and CD44 in the development of dimethylnitrosamine-induced liver cirrhosis. *Journal of Gastroenterology Hepatology*, *15*, 402–411.
- Scoazec, J. -Y. (1995). Expression of cell–matrix adhesion molecules in the liver and their modulation during fibrosis. *Journal of Hepatology*, *22*(Suppl 2), 20–27.
- Sherman, L., Sleeman, J., Herrlich, P., & Ponta, H. (1994). Hyaluronate receptors: Key players in growth, differentiation, migration and tumor progression. *Current Opinion in Cell Biology*, *6*, 726–733.
- Shiba, M., Shimizu, I., Yasuda, M., Ii, K., & Ito, S. (1998). Expression of type I and type III collagens during the course of dimethylnitrosamine-induced hepatic fibrosis in rats. *Liver*, *18*, 196–204.
- Stickel, F., Urbaschek, R., Schuppan, D., Poeschl, G., Oesterling, C., Conrad, C., McCuskey, R. S., Simanowski, U. A., & Seitz, H. K. (2001). Serum collagen type VI and XIV and hyaluronic acid as early indicators for altered connective tissue turnover in alcoholic liver disease. *Digestive Disease and Sciences*, *46*, 2025–2032.
- Tamaki, S., Ueno, T., Torimura, T., Sata, M., & Tanikawa, K. (1996). Evaluation of hyaluronic acid binding ability of hepatic sinusoidal endothelial cells in rats with liver cirrhosis. *Gastroenterology*, *111*, 1049–1057.
- Toole, B. P. (2001). Hyaluronan in morphogenesis. *Seminars in Cell and Developmental Biology*, *12*, 79–87.
- Tsutsumi, R., Leo, M. A., Kim, C. I., Tsutsumi, M., Lasker, J., Lowe, N., & Lieber, C. S. (1990). Interaction of ethanol with enflurane metabolism and toxicity role: Of P450IIE1. *Alcohol Clinical and Experimental Research*, *14*, 174–179.
- Tsutsumi, M., Urashima, S., Takase, S., Ueshima, Y., Tsuchishima, M., Shimanaka, K., & Kawahara, H. (1997). Characteristics of serum hyaluronate concentrations in patients with alcoholic liver disease. *Alcohol Clinical and Experimental Research*, *21*, 1716–1721.
- Ueno, T., Inuzuka, S., Torimura, T., Tamaki, S., Koh, H., Kin, M., Minetoma, T., Kimura, Y., Ohira, H., Sata, M., Yoshida, H., & Tanikawa, K. (1993). Serum hyaluronate reflects hepatic sinusoidal capillarization. *Gastroenterology*, *105*, 475–481.
- Urashima, S., Tsutsumi, M., Shimanaka, K., Ueshima, Y., Tsuchishima, M., Itoh, T., Kawahara, H., & Takase, S. (1999). Histochemical study of hyaluronate in alcoholic liver disease.

- Alcohol Clinical and Experimental Research*, 23(Suppl 4), 56S–60S.
- Urashima, S., Tsutsumi, M., Ozaki, K., Tsuchishima, M., Shimanaka, K., Ueshima, Y., & Takase, S. (2000). Immunohistochemical study of hyaluronate receptor (CD44) in alcoholic liver disease. *Alcohol Clinical and Experimental Research*, 24, 34s–38s.
- Vrochides, D., Papanikolaou, V., Pertoft, H., Antoniadis, A. A., & Heldin, P. (1996). Biosynthesis and degradation of hyaluronan by nonparenchymal liver cells during liver regeneration. *Hepatology*, 23, 1650–1655.
- Yasuda, M., Nakano, K., Yasumoto, K., & Tanaka, Y. (2002). CD44: Functional relevance to inflammation and malignancy. *Histology Histopathology*, 17, 945–950.